

TOTAL PANCREATECTOMY WITH AUTOLOGUS ISLET CELLS TRANSPLANTATION

Eliza GANGONE¹, Dragos ROMANESCU¹, Mihaela CHIVU-ECONOMESCU², Coralia BLEOTU²,
Dana TOMESCU¹, Simona CARNICIU³, Cristian GUJA³, Simona DIMA¹,
Constantin IONESCU-TÎRGOVIȘTE³ and Irinel POPESCU¹

¹Center of General Surgery and Liver Transplantation “Dan Setlacec”, Fundeni Clinical Institute, Bucharest, Romania

²Stefan S. Nicolau Institute of Virology, Bucharest, Romania

³“Nicolae Paulescu” National Institute for Diabetes, Nutrition and Metabolic Diseases, Bucharest, Romania

Corresponding author: Simona DIMA, E-mail: simona@romhealth.ro

Received December 2, 2012

Chronic pancreatitis is a progressive inflammatory disease destroying secretory pancreatic parenchyma. Total pancreatectomy and islet autotransplantation (IAT) is a viable option in selected patients in order to decrease mortality and improve hyperglycemia. Duodenum and spleen preserving total pancreatectomy and islet autotransplantation was done in 53 years old woman, with chronic pancreatitis affecting the whole pancreas. Human islet isolation was performed in the Fundeni GMP Laboratory, after informed consent has been obtained. Trimmed and cannulated pancreas was distended with enzymatic solution containing: 20U/g pancreas GMP grade NB1 collagenase and 0.6U/g pancreas neutral protease in HBSS solution by injection of cold enzyme solution through the pancreatic duct using a perfusion Biorep system. The digestion was performed using automated method in a Ricordi chamber maintaining temperature between 32⁰C and 38⁰C. Dissociation of the pancreas and appearance of free islets was monitored by periodically stained with 0.1% dithizone (DTZ) solution. Resulted islets were wash for two time in Wash Solution and were loaded in transplantation islet infusion bag. 4700 islets equivalent/kilogram (IEQ/kg) were infused via an inferior mesenteric vein catheter into the portal system with portal pressure monitoring during infusion in ICU. The clinical follow-up at one years post IAT indicated free of insulin status. This demonstrates that total pancreatectomy with autologus islet cells transplantation can be an appropriate and successful therapeutically approach.

Key words: chronic pancreatitis, total pancreatectomy, islet isolation.

INTRODUCTION

Chronic pancreatitis (CP) is a progressive inflammatory disease, in which pancreatic parenchyma is replaced by extensive fibrotic tissue, in both components: exocrine and endocrine. The final result of the pancreatic tissue replacement is the loss of the pancreatic function, which leads to both exocrine and endocrine insufficiency (i.e. malnutrition and diabetes), and decrease of the quality of life by chronic abdominal recurrent pain and narcotic dependence¹. The main goals of the CP treatment are: relieve intractable pain, to correct surgical

induced metabolic insufficiency (diabetes, malnutrition) and to conserve as much as possible the unaffected pancreatic tissue¹.

However, in a subset of patients that do not respond to minimally invasive techniques or “parenchyma-sparing” procedures the total pancreatectomy is performed.

Total pancreatectomy (TP) is considered a major surgical operation, that require specific trained surgeons, and a multidisciplinary team, involved in preoperative evaluation as well as in the monitoring or treatment of the surgical and metabolic complications.

Historically, from the surgical point of view the total pancreatectomy was avoided due to the high rate of mortality and morbidity². In the last three decades the mortality rate decreased from 22% to 3% mainly due to the improved surgical technique³.

One of the major postoperative complications is represented by the complete insulin and glucagon deficiency, which lead to “surgical induced diabetes”⁴.

High-volume centers for pancreatic surgery are associated with reduced mortality and morbidity rates after this major surgical procedure. Center of General Surgery and Liver Transplantation of Fundeni Clinical Institute is considered high-volume center for pancreatic surgery.

Büchler MW. *et al.* have demonstrated that mortality and morbidity rates after elective TP are not significantly different from the pylorus preserving pancreatoduodenectomy⁵.

By TP, the entire pancreas is removed, but also the nerve injury caused by pancreas inflammation is stopped⁶.

Total pancreatectomy followed by islet cell autotransplantation (IAT) has become a treatment approach in selected patients with chronic pancreatitis (CP) and intractable pain. The first islet autograft was done at the University of Minnesota in 1977, for a painful small duct CP. The long-term results was favorable and patient became insulin and pain free^{7,8}.

According to the recent published paper, since 1977, more than 500 islet autotransplantation have been performed worldwide⁹. Recently, Sutherland *et al.* reported the largest series of total pancreatectomy and IAT at University of Minnesota, and 409 patients with CP and IAT were reported^{1,4}.

We present here our results regarding a patient with total pancreatectomy who had undergone islet transplantation, and a literature review on islet autotransplantation in total pancreatectomy for chronic pancreatitis.

MATERIALS AND METHODS

Preoperative evaluation

53 year's old, female, 60 kg, BMI 22.

Laboratory test: HbA1C: 6.3% (normal range: 4.8–6.0%), and plasma glucose. CT scan and MRI have shown the presence of small duct chronic pancreatitis with cysts in the whole pancreas.

The indication for surgery was chronic pancreatitis affecting the whole pancreas, with abdominal pain refractory to medical therapy.

Surgical Resection

Surgical technique of total duodenum and spleen preserving total pancreatectomy has been performed.

During the operation, blood supply to the pancreas was preserved for as long as possible to minimize warm ischemia to the islet cells. Typically, the distal portion of the pancreas was mobilized initially and divided, along with the splenic artery and vein, at the level of the superior mesenteric vein.

Meticulous dissection and attention to haemostasis is crucial as the risk of bleeding is increased because full heparinization is carried out prior to islet infusion and the islet infusion induces transient portal hypertension.

The inferior mesenteric vein (IMV) was cannulated for islet infusion into the portal system (Figure 1).

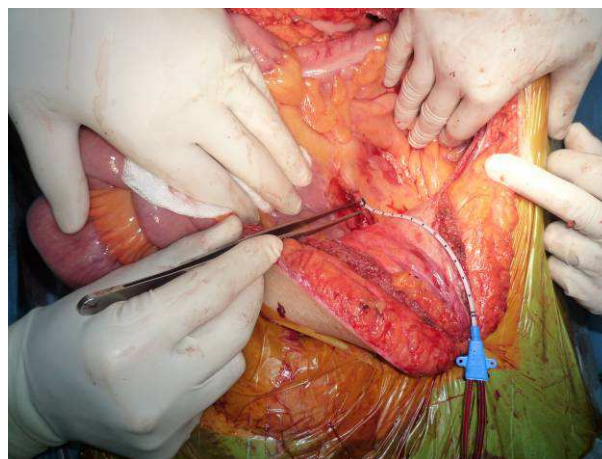


Fig. 1. Cannulation of the IMV by using 112 –F angiocath - intraoperative aspect.

Islet isolation and evaluation, infusion

The isolation was performed in the Fundeni Clinical Institute Islet Isolation Facility, based on Ricordi modified isolation method^{10,11}, in compliance with Romanian legislation regarding cell therapy. Written informed consent of the patient was signed before surgery.

Pancreas distension during enzyme infusion was evaluated as previously described¹².

The islets are isolated from the surrounding exocrine and connective tissue by a stepwise modified Ricordi method consisted in:

- intraductal enzymatic infusion (collagenase digestion)
- pancreatic tissue digestion at 37°C using Ricordi islet isolation machine with Ricordi chamber (enzymatic and mechanic dissociation)
- cooling the digested pancreatic tissue, dilution and islet collection (the digestion is stopped)
- transplantation of the unpurified fresh (not cultured) final product

Digestion time is represented by the time needed to release sufficient number of islets from acinar tissue.

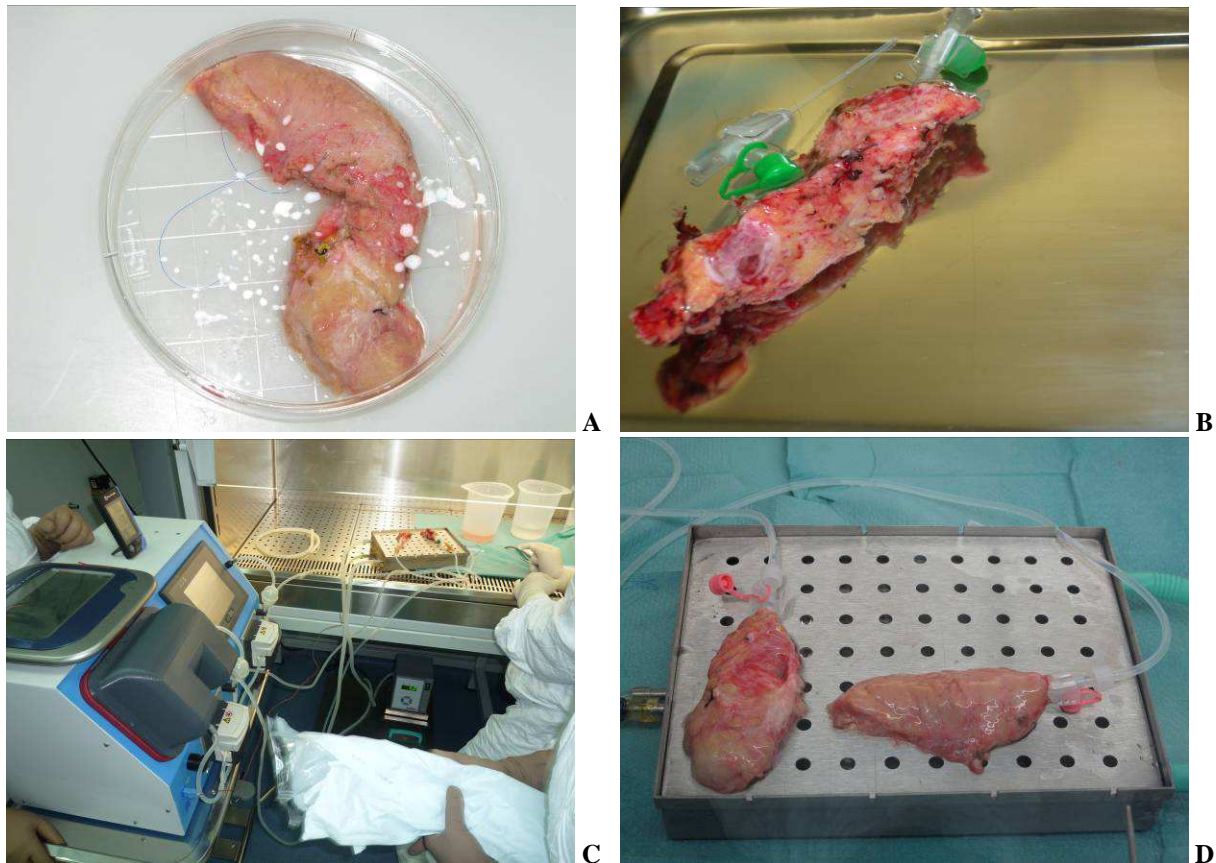


Fig. 2. Intraductal enzymatic infusion of pancreas: (A) trimmed pancreas, (B) Cannulated pancreas, (C) Perfusion system for enzyme infusion; (D) Distended pancreatic fragment head and tail.

The islet yield and purity were determined by light microscopy after staining with dyphenylthiocarbazon (Sigma, St. Louis, USA). Islet number was converted to islet equivalent (IEQ): diameters standardizing to 150 μm . The final product was assessed for sterility as previously described¹³.

Isolated islets were resuspended in an infusion bag with CMRL Islet Transplant (Mediatech, Inc) and 5% human serum albumin and heparin (70 U/kg) to prevent intraportal clotting. Portal pressures are checked intermittently during islet infusion.

Post-transplantation care and evolution

Metabolic assessment included: daily plasma glucose measurement (glucose-oxidase method), HbA1c, (HPLC method) C-peptide and plasma insulin level (ELISA method) and, HOMA -IR and HOMA-B obtained from fasting plasma glucose and plasma insulin (<http://www.hcvsociety.org/files/HOMACalc.htm>)

In the postoperative period, the insulin infusion was initiated in order to maintain the blood glucose in the range of 70-140 mg/dl. We define as insulin independent if patient is without insulin therapy, with positive value of C-peptide, fasting blood glucose <140 mg/dl

Engraftment and function of transplant islets were assessed by HOMA index (homeostasis model assessment). HOMA predict homeostasis from varying degrees of beta cell function and insulin resistance. HOMA IR (insulin resistance) and beta cell function can be estimated from fasting glucose and insulin levels. HOMA B is useful in assessing functional

islet mass. Its formula includes plasma concentration of insulin, and therefore cannot evaluate islet function for patients receiving exogenous insulin¹⁴.

Pain assessment

Pain was scored on a visual scale from 0 (no pain) to 10 (severe pain).

RESULTS AND DISCUSSION

Outcome of the islet isolation

The excised pancreas weighed 80g. The removed chronic altered acinar pancreas was placed in cold preservation solution (Custodiol). The next step was to split the pancreas into two sections: head and body/ tail. Pancreatic duct cannulated with 16G catheter, connected to the Biorep perfusion machine.

The pancreas was distended with enzymatic solution containing: 20U/g pancreas GMP grade NB1 collagenase and 0.6U/ g pancreas neutral protease (Serva Electrophoresis, GmbH, Germany). During infusion of enzyme the good distension was observed (Figure 2).

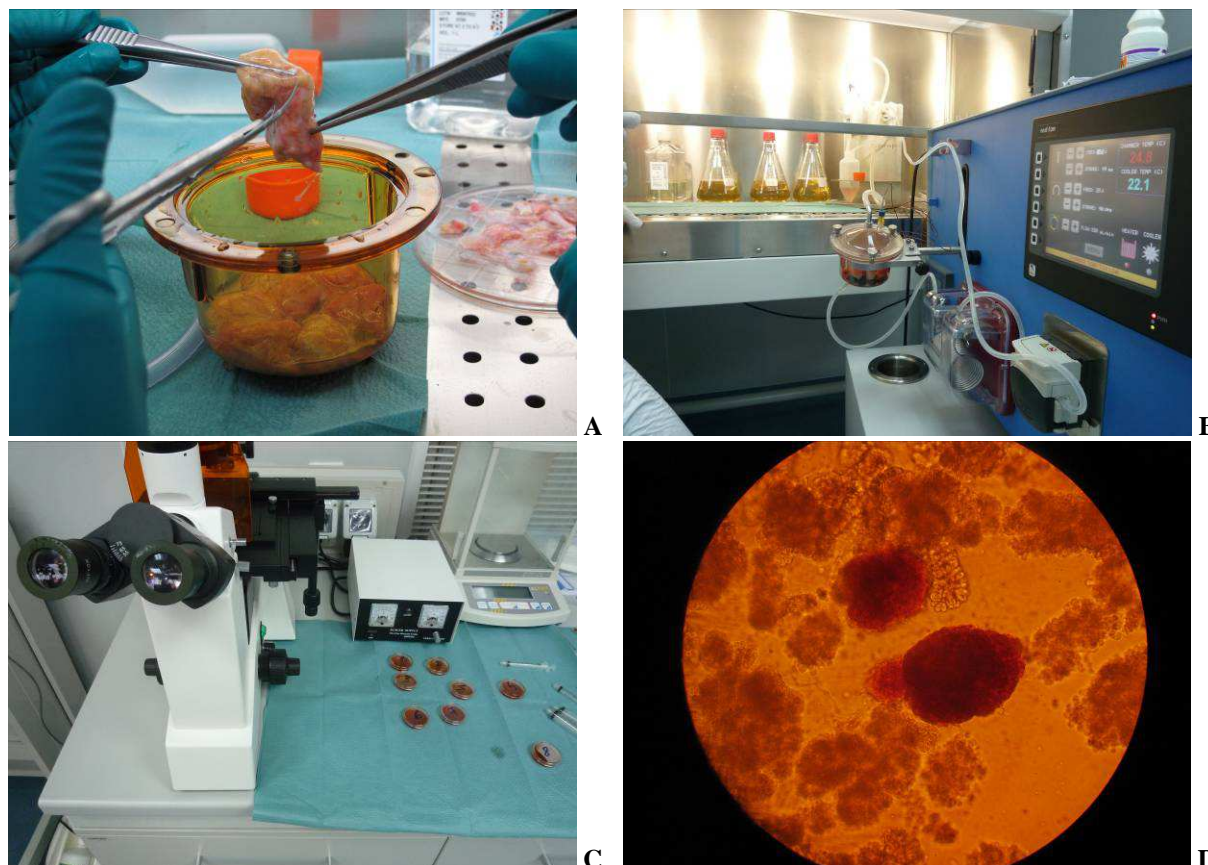


Fig. 3. The digestion of pancreas performed using automated Ricordi chamber (A, B); Dissociation of the pancreas and appearance of free islets monitored by periodically stained with 0.1% dithizone (DTZ) solution (C); Free islet stained in red with dithizone (200 \times) (D).

The distended pancreas was cut in 11 pieces and then transferred to the Ricordi digestion chamber. The Ricordi chamber was connected to a modified, closed circulation tubing system, warmed up to 37 $^{\circ}$ C and shaken gently during the digestion process. Samples were taken continuously to monitor the digestion process (Figure 3). Periodically 1 mL of sample was taken from the sample port with a syringe, stained with dithizone (DTZ) solution and observed under a microscope. Once free islets were detected under the microscope, the digestion was stopped by flushing cold (4 $^{\circ}$ C) dilution solution (Mediatech, Herndon, VA) into the circulation system to dilute the enzyme.

The digested product was collected and washed in media supplemented with human albumin. The total islet yield obtained after the isolation with no purification was 4700 IE/ Kg. After performing sterility test cellular product was loaded in transplant bag. The perfusion time was 12 minutes, and the islet preparation time was 5 hours. The prepared islets were infused into the IMV during a 40 minutes.

The correlation of the islet function with islet yield

Pancreatized patients developed “surgical diabetes”, a brittle diabetes with blood glucose variability, and hypoglycemic episodes.

Pain relief is reported to be achieved in approximately 80% of patients with IAT after TP.

Overall, 30% to 40% achieve insulin independence, and 70% of recipients remain insulin independent for > 2 years, especially if the number of the infused islets > 300 000¹⁵.

Sutherland *et al.* demonstrated a strong correlation between islet yield and post islet autotransplantation metabolic function^{1,3}.

The islet yield achieved after the islet isolation is dependent on the degree of histopathological changes, such as irreversible fibrosis, acinar atrophy, and inflammation. Kobayashi argued that taking into account the inversely correlation between the pancreatic fibrosis and islet yield, the decision to perform total pancreatectomy with IAT should be done in the early stage of CP¹⁶.

One report of the University of Minnesota team have shown that if more than 5000 IE/Kg are autotransplanted after total pancreatectomy, the insulin independence was achieved in 63% of patients^{17,18}.

Islet engraftment site

The site of the transplantation is also very important for insulin delivery.

The liver infusion site has some disadvantages^{19,20}:

- in the liver the islets are exposed to the locally inflammatory factors, such as cytokines, chemokines, and oxidative stress mediators.

- The greater gluco-lipototoxicity

- Direct exposure to the portal blood.

Despite the most common site for islet infusion is the liver, there are some different options such as: peritoneal cavity, omental, intramuscular²¹⁻²⁴. One important aim of the infusion of islets in the extrahepatic site is to avoid hypoxia until the neovessels formation.

Table 1

Clinical outcome of the patient following autotransplantation of pancreatic islets*

Parameter	2 weeks	3 months	9 months	1 year	1.5 years
Plasma glucose level	129	109	117	100	108
HbA1c**	6.1	6.21	6.08	6.08	5.88
Insulin	4.19	3.68	2.76	4.20	2.27
c-peptid	1.36	1.43	1.05	1	0.889
HOMA-beta (B)	60	68	48	40.8	49.9
HOMA IR	1.1	1.1	0.8	1.04	0.7
SUITO***	29.7	46.65	29.25	40.65	29.61

* The patient has a very good quality of life, and is pain free, insulin independent;

** Normal value HbA1c: 4.8–6.0%

*** SUITO-Secretory Unit of Islet Transplant Objects³²

Even if for the presented case we used the islet infusion into the liver through the portal vein, our hypothesis is that the greater omentum fits the required specifications for the ideal site of islet engraftment.

Ao *et al.* have shown the reversal of the “surgical diabetes” after the total pancreatectomy and purified islets autotransplanted into the greater omental pouch²⁵.

The greater omentum has angiogenic property, and allows for good neoangiogenesis^{26,27}.

The angiogenic potential of the recipient tissue have an important role in the process of graft engraftment²⁸. It was suggested that angiogenic stimulation by VEGF (vascular endothelial growth factor) may promote the development of an islet vascular supply²⁹.

One major advantage of the omentum in case of unpurified islets is that the omentum allows the infusion of increased graft volume that means also an increased transplanted islet mass.

Rafael E *et al.* reported a case of islet autotransplantation in the forearm of the total pancreatectomized 7-year old child. Patient has

well controlled diabetes, with no recurrent episodes of hypoglycemia that requires small doses of insulin²³.

Advantages or disadvantages of the islet purification

Unpurified islets as the source of new islets

In the case reported by us the pancreatic islets have not been purified.

The unpurified islet preparation combines the acinar free islets, islet clusters, the acinar tissue, including the ductal cells. In our study 40% of the isolated islets are embedded within acinar tissue, and the final product has low purity. By transplantation of unpurified substantial mass of nonendocrine cells, mainly acinar cells and PDC (Pancreatic Ductal Cells) are also implanted. The presence of the nonendocrine subset of cells may be beneficial for the long-term metabolic function of the transplanted islets³⁰.

Pancreatic ductal precursor cells (PDC) may represent a source of islet neogenesis in patients with CP. There are some published studies that

suggest the islet neogenesis from ductal progenitor cells. Islet neogenesis from ductal progenitor cells was found in the biopsies of three patients with islet autotransplantation reported by Soltani SM. The obtained “islet-like” structures are positive for insulin and glucagon staining³¹.

Low tissue volume = low complication rate?

Usually in islet autotransplantation after TP, the purification is rarely applied because is considered that the amount of the exocrine tissue is limited. Matsumoto et al has found that purification can reduce the risk of complications when the tissue volume is high³².

On the other hand, the major disadvantages of the islet purification is that 40% of the islet cell mass is lost during purification^{33,34}. This observation is very important in the context in which, the main concern, regarding complications is the high volume of tissue that could increase the portal pressure.

CONCLUSIONS

Combined total pancreatectomy and autotransplantation can be a safe surgical procedure, which relieve the pain and also ensure the insulin independence.

ACKNOWLEDGEMENT

This paper is partly supported by the Sectorial Operational Programme Human Resources Development, financed from the European Social Fund and by the Romanian Government under the contract nr. POSDRU/88/1.5/S/64331 and POSDRU 89/1.5/S/60746.

REFERENCES

- Sutherland DE, Radosevich DM, Bellin MD, Hering BJ, Beilman GJ, Dunn TB, Chinnakotla S, Vickers SM, Bland B, Balamurugan AN, Freeman ML, Pruetz TL. Total pancreatectomy and islet autotransplantation for chronic pancreatitis. *J Am Coll Surg* 2012;214(4):409-24.
- Nathan H, Wolfgang CL, Edil BH, Choti MA, Herman JM, Schulick RD, Cameron JL, Pawlik TM. Perioperative mortality and long-term survival after total pancreatectomy for pancreatic adenocarcinoma: a population-based perspective. *J Surg Oncol* 2009; 99(2):87-92.
- Dong M, Parsaik AK, Erwin PJ, Farnell MB, Murad MH, Kudva YC. Systematic review and meta-analysis: islet autotransplantation after pancreatectomy for minimizing diabetes. *Clin Endocrinol (Oxf)* 2011; 75(6):771-9.
- Bellin MD, Balamurugan AN, Pruetz TL, Sutherland DE. No islets left behind: islet autotransplantation for surgery-induced diabetes. *Curr Diab Rep* 2012; 12(5):580-6.
- Muller MW, Friess H, Kleeff J, Dahmen R, Wagner M, Hinz U, Breisch-Girbig D, Ceyhan GO, Buchler MW. Is there still a role for total pancreatectomy? *Ann Surg* 2007; 246(6):966-74.
- Morrison CP, Wemyss-Holden SA, Dennison AR, Maddern GJ. Islet yield remains a problem in islet autotransplantation. *Arch Surg* 2002;137(1):80-3.
- Sutherland DE, Matas AJ, Najarian JS. Pancreatic islet cell transplantation. *Surg Clin North Am* 1978; 58(2):365-82.
- Najarian JS, Sutherland DE, Matas AJ, Goetz FC. Human islet autotransplantation following pancreatectomy. *Transplant Proc* 1979; 11(1):336-40.
- Ris F, Niclauss N, Morel P, muylder-Mischler S, Muller Y, Meier R, Genevay M, Bosco D, Berney T. Islet autotransplantation after extended pancreatectomy for focal benign disease of the pancreas. *Transplantation* 2011; 91(8):895-901.
- Ricordi C, Lacy PE, Scharp DW. Automated islet isolation from human pancreas. *Diabetes* 1989; 38 Suppl 1:140-2.
- Matsumoto S, Okitsu T, Iwanaga Y, Noguchi H, Nagata H, Yonekawa Y, Yamada Y, Fukuda K, Shibata T, Kasai Y, Maekawa T, Wada H, Nakamura T, Tanaka K. Successful islet transplantation from nonheartbeating donor pancreata using modified Ricordi islet isolation method. *Transplantation* 2006;82(4):460-5.
- Takita M, Naziruddin B, Matsumoto S, Noguchi H, Shimoda M, Chujo D, Itoh T, Sugimoto K, Onaca N, Lamont JP, Lara LF, Levy MF. Variables associated with islet yield in autologous islet cell transplantation for chronic pancreatitis. *Proc (Bayl Univ Med Cent)* 2010; 23(2):115-20.
- Matsumoto S, Takita M, Shimoda M, Sugimoto K, Itoh T, Chujo D, Sorelle JA, Tamura Y, Rahman AM, Onaca N, Naziruddin B, Levy MF. Impact of tissue volume and purification on clinical autologous islet transplantation for the treatment of chronic pancreatitis. *Cell Transplant* 2012;21(4):625-32.
- Matthews DR, Hosker JP, Rudenski AS, Naylor BA, Treacher DF, Turner RC. Homeostasis model assessment: insulin resistance and beta-cell function from fasting plasma glucose and insulin concentrations in man. *Diabetologia* 1985; 28(7):412-9.
- Bellin MD, DE RS, Robertson RP. Pancreatectomy and autologous islet transplantation for painful chronic pancreatitis: indications and outcomes. *Hosp Pract (Minneapolis)* 2012; 40(3):80-7.
- Kobayashi T, Manivel JC, Carlson AM, Bellin MD, Moran A, Freeman ML, Bielman GJ, Hering BJ, Dunn T, Sutherland DE. Correlation of histopathology, islet yield, and islet graft function after islet autotransplantation in chronic pancreatitis. *Pancreas* 2011; 40(2):193-9.
- Sutherland DE, Gruessner AC, Carlson AM, Blondet JJ, Balamurugan AN, Reigstad KF, Beilman GJ, Bellin MD, Hering BJ. Islet autotransplant outcomes after total pancreatectomy: a contrast to islet allograft outcomes. *Transplantation* 2008;86(12):1799-802.
- White SA, Dennison AR, Swift SM, Davies JE, Clayton HA, Burden AC, Musto PP, Johnson PR, Wicks A, London NJ. Intraportal and splenic human islet

- autotransplantation combined with total pancreatectomy. *Transplant Proc* 1998; 30(2):312-3.
19. Bennet W, Groth CG, Larsson R, Nilsson B, Korsgren O. Isolated human islets trigger an instant blood mediated inflammatory reaction: implications for intraportal islet transplantation as a treatment for patients with type 1 diabetes. *Ups J Med Sci* 2000;105(2):125-33.
 20. Moberg L. The role of the innate immunity in islet transplantation. *Ups J Med Sci* 2005;110(1):17-55.
 21. Bellin MD, Freeman ML, Schwarzenberg SJ, Dunn TB, Beilman GJ, Vickers SM, Chinnakotla S, Balamurugan AN, Hering BJ, Radosevich DM, Moran A, Sutherland DE. Quality of life improves for pediatric patients after total pancreatectomy and islet autotransplant for chronic pancreatitis. *Clin Gastroenterol Hepatol* 2011; 9(9):793-9.
 22. Blondet JJ, Carlson AM, Kobayashi T, Jie T, Bellin M, Hering BJ, Freeman ML, Beilman GJ, Sutherland DE. The role of total pancreatectomy and islet autotransplantation for chronic pancreatitis. *Surg Clin North Am* 2007; 87(6):1477-501, x.
 23. Rafael E, Tibell A, Ryden M, Lundgren T, Savendahl L, Borgstrom B, Arnelo U, Isaksson B, Nilsson B, Korsgren O, Permert J. Intramuscular autotransplantation of pancreatic islets in a 7-year-old child: a 2-year follow-up. *Am J Transplant* 2008; 8(2):458-62.
 24. Yasunami Y, Lacy PE, Finke EH. A new site for islet transplantation--a peritoneal-omental pouch. *Transplantation* 1983; 36(2):181-2.
 25. Ao Z, Matayoshi K, Lakey JR, Rajotte RV, Warnock GL. Survival and function of purified islets in the omental pouch site of outbred dogs. *Transplantation* 1993; 56(3):524-9.
 26. Liebermann-Meffert D. The greater omentum. Anatomy, embryology, and surgical applications. *Surg Clin North Am* 2000; 80(1):275-93, xii.
 27. Rajab A. Islet transplantation: alternative sites. *Curr Diab Rep* 2010; 10(5):332-7.
 28. Stagner JI, Mokshagundam SP, Samols E. Induction of mild hypoglycemia by islet transplantation to the pancreas. *Transplant Proc* 1998; 30(2):635-6.
 29. Kuroda M, Oka T, Oka Y, Yamochi T, Ohtsubo K, Mori S, Watanabe T, Machinami R, Ohnishi S. Colocalization of vascular endothelial growth factor (vascular permeability factor) and insulin in pancreatic islet cells. *J Clin Endocrinol Metab* 1995; 80(11):3196-200.
 30. Ichii H, Miki A, Yamamoto T, Molano RD, Barker S, Mita A, Rodriguez-Diaz R, Klein D, Pastori R, Alejandro R, Inverardi L, Pileggi A, Ricordi C. Characterization of pancreatic ductal cells in human islet preparations. *Lab Invest* 2008; 88(11):1167-77.
 31. Soltani SM, O'Brien TD, Loganathan G, Bellin MD, Anazawa T, Tiwari M, Papas KK, Vickers SM, Kumaravel V, Hering BJ, Sutherland DE, Balamurugan AN. Severely fibrotic pancreases from young patients with chronic pancreatitis: evidence for a ductal origin of islet neogenesis. *Acta Diabetol* 2011 July 20.
 32. Matsumoto S, Noguchi H, Hatanaka N, Shimoda M, Kobayashi N, Jackson A, Onaca N, Naziruddin B, Levy MF. SUIITO index for evaluation of efficacy of single donor islet transplantation. *Cell Transplant* 2009; 18(5):557-62.
 33. Bramis K, Gordon-Weeks AN, Friend PJ, Bastin E, Burls A, Silva MA, Dennison AR. Systematic review of total pancreatectomy and islet autotransplantation for chronic pancreatitis. *Br J Surg* 2012; 99(6):761-6.
 34. Garcea G, Weaver J, Phillips J, Pollard CA, Ilouz SC, Webb MA, Berry DP, Dennison AR. Total pancreatectomy with and without islet cell transplantation for chronic pancreatitis: a series of 85 consecutive patients. *Pancreas* 2009; 38(1):1-7.