

EXPERIMENTAL STUDY REGARDING CHANGES OF MEDIO-SAGITTAL SUTURE POST-DISJUNCTION ON COMMON BREED RABBIT

Ruxandra BARTOK¹, Constantin VARLAN¹, Radu STANCIU¹, Bogdan DIMITRIU¹,
Oana AMZA¹, Ileana SUCIU¹, Sanziana SCARLATESCU¹, Irina GHEORGHIU¹, and Ioana SUCIU¹

¹“Carol Davila” University of Medicine and Pharmacy, Bucharest, Romania
E-mail: joa_suciu@yahoo.com

Accepted January 16, 2015

Intermaxillary disjunction is defined as the release of medio-palatine suture using mechanical forces. The role of this procedure is to expand the upper jaw in order to achieve the broadening of the upper arch. The present paper is an experimental research on regarding medio-sagittal suture post disjunction in order to study the bone changes which are taking place as a result of the split of median maxillary suture. The disjunctors were applied on laboratory animals, activated in one sitting. Radiological estimates pre- and post-disjunction and also, CT evaluation was carried out in two points, namely, at the end of the active phase of expansion and after contention. The results demonstrates that the therapeutic method induces permanent structural bone changes, offering an additional guarantee as in terms of maintaining the stability of the orthodontic treatment outcome, but further studies have to be done as the animal laboratory testing findings are not directly transferable to human tissue.

Keywords: intermaxillary disjunction; medio-palatine suture; maxilar bone; ortodontic treatment.

INTRODUCTION

Expanding the upper jaw by releasing median suture is a relatively common clinical procedure. This research has proposed, on a common strain of rabbit breed, a study on bone changes produced by the split of median maxillary suture in an attempt to emphasize that the purpose of this therapeutic technique is to obtain additional bone. Of course, changes on rabbit desmal tissue can not be treated as an overall human ones.

Intermaxillary disjunction is defined as the release of medio-palatine suture using an orthopedic forces. Thus, the yield is expansion of the upper jaw transversely. According to Boboc¹⁶ “intermaxillary disjunction offers the possibility that in a short time to achieve considerable broadening of the upper arch, hard palate, nasal and even the face.”

MATERIAL AND METHODS

The disjunction technique requires two essential characteristics, *i.e.* a firm anchorage on the sides

and using a device that can cope with the disjunction separating effort on medio-sagittal suture^{7,8}.

Therefore, there were developed two metal trays to size rodent's side areas, on a dry skull, allowing, on the one hand, getting a model easy to use and fingerprinting to build the disjunctors.

Given that the experiment rabbits were part of the same strain, individual modifications of the lateral sides proved minimal (common breeds rabbits had an average weight of about 2700 g). In order to individualize the contact between the metal trays and the dental sector, there have been practiced retentions in trays, which were fixed to the sides by means of a self-curing material. Thus, the developed devices have been used throughout the batch of studied rabbits and in some cases reused on experimental animals.

It was used a Dentaurum screw type for disjunction, with parallel outlets, whose arms were welded to the metal trays (Fig. 1).

Thereafter, radiological estimates pre- and post-disjunction were obtained, at the same time intervals at which measurements were performed on the width of the base jaws, using computerized tomography, measuring the upper intermolar distance of the first maxillary molar.

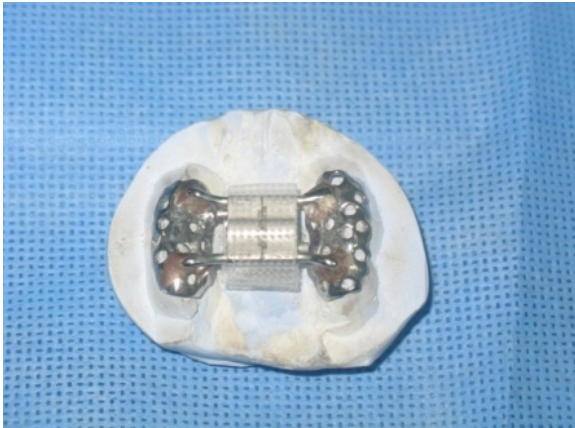

Fig. 1. The disjunctive – using a Dentaurum screw type, whose arms were welded to the metal trays.

In agreement with previous studies^{5,9,11} our determinations on the bone post-disjunction effects showed similar results.

The disjunctive were applied to a total of 9 rabbits (using groups of 3 rabbits) (Figs. 2, 3).

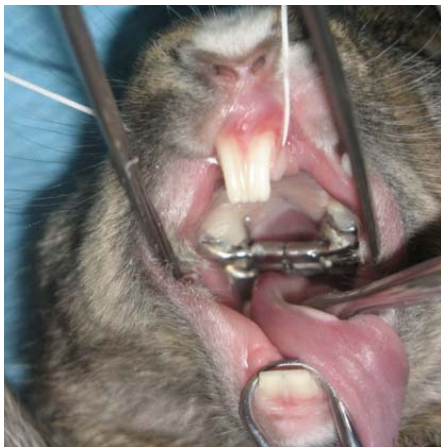

Fig. 2. After applying the disjunctive.

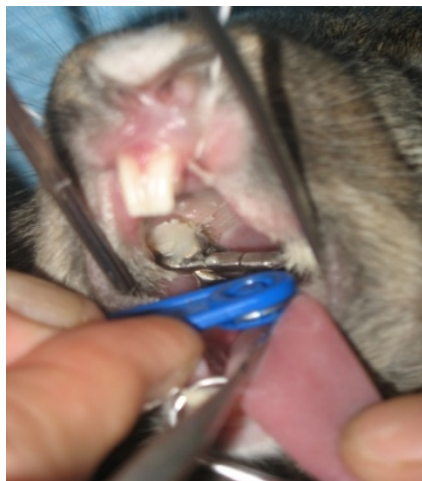


Fig. 3. Activating the disjunctive.

On 9 rabbits the disjunctive were cemented on the premolars and molars of the upper arch, on each side of the center line, with a self-curing material (Structur 2, Voco, Germany).

The disjunctive were then activated in one sitting (rapid maxillary expander) (Fig. 3). The first group of rabbits was euthanized immediately after setting and activating the devices, using general anesthesia was practiced neuroleptanalgesia with Acepromazine 0.4 mg/kg body and Ketamine 0.5 mg/kg body, the second group after 7 days, and the third one after 14 days.

RESULTS AND DISCUSSION

It was found that the orthopedic forces developed by the disjunction device produced the split of the medio-sagittal suture, which caused the onset of a process of tissue repair^{5,12} and finally the formation of new bone.

The osteo-forming activity is predominant, following the osteoclasts wave, with dense mesenchymal tissue^{4,6} and with the presence of very active osteoblasts, in contact with lamellar bone on which primitive bone is formed, due to microfracture that occurred after traction (Fig. 4).

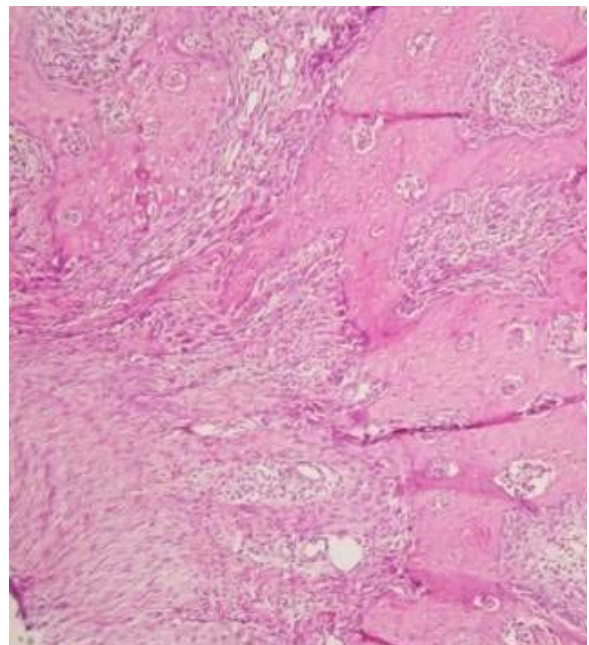


Fig. 4. Predominantly osteo-forming activity with the presence of mesenchymal tissue and osteoblasts adjacent to lamellar bone.

The next image presents a net tendency to suture closure by new bone tissueforming

(Fig. 5). It signals the presence of immature nonlamellar bone crack on lateral slopes and the presence of osteocytes in mature lamellar bone.

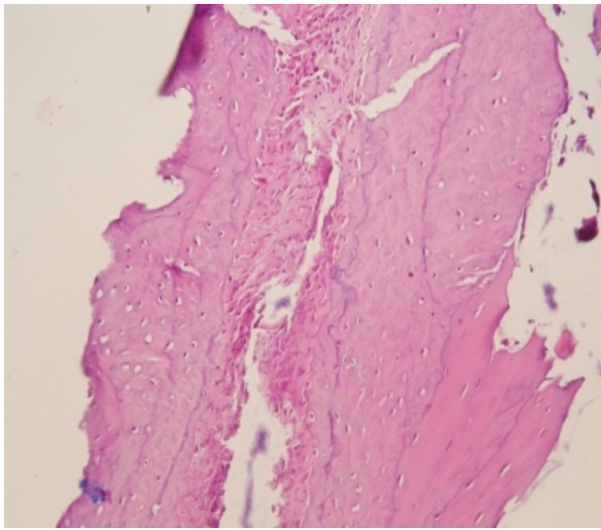


Fig. 5. Closing of the crack trend on median suture surrounding, throughout the ossification process.

Most studies indicate that the newly formed bone require longer periods of consolidation^{1,2,9,11}. After consolidation, which can be considered as early as 2 weeks up to 3 months after disjunction, were recorded the best results on animal models, without the regenerated bone to evidence (in a qualitatively or quantitatively manner) characters of a normal bone, under the conditions that bone remodeling may take up to a year or more.

In this study we demonstrated and objectified the fact that the split of the medio- palatine suture on experimental animal is possible on “in vivo” system, interpreting the bone and cartilage cell response to mechanical force. Thus, the expansion force acting along the suture, induced bone resorption by activation of the osteoblast, as well as by formation of new bone, due to the proliferation and differentiation of periosteal cells.

There have been recorded pre- disjunction (Fig. 6) and post-disjunction (Figs. 7, 8) radiological estimates at the same time intervals at which there have been made histological estimates, as well.

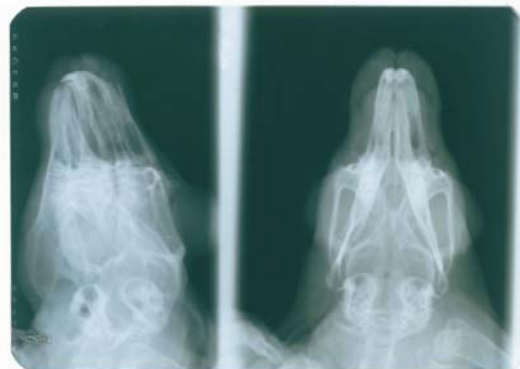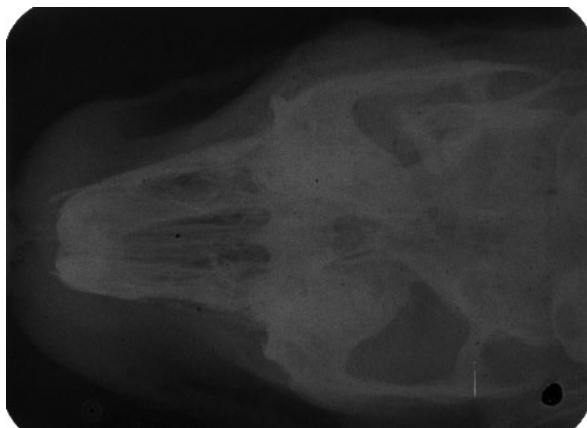


Fig. 6. Axial and lateral angulation – radiographic image obtained before the disjunction.

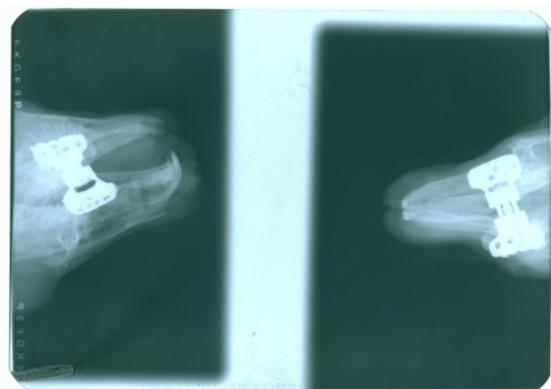
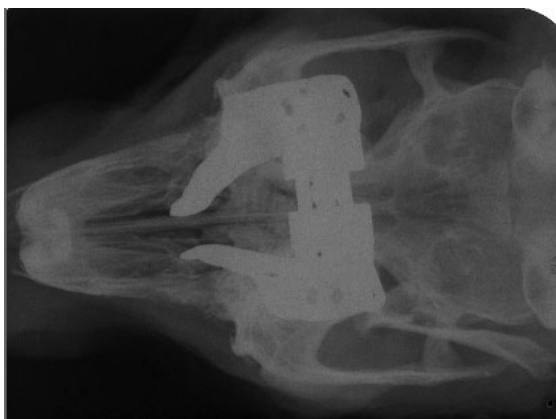

Fig. 7. Axial and lateral angulation – radiographic image obtained at the end of the active phase of expansion (with modified disjunctur).

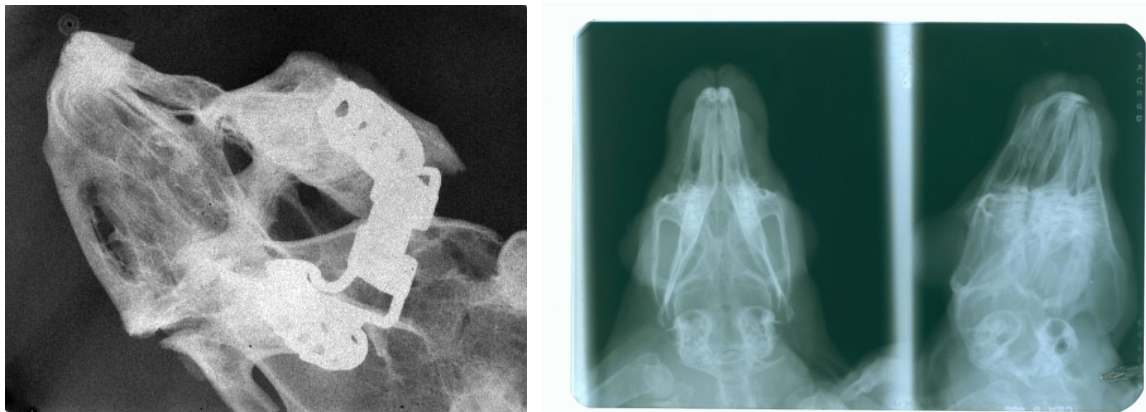


Fig. 8. X-ray image obtained after disjunction (lateral and axial view).

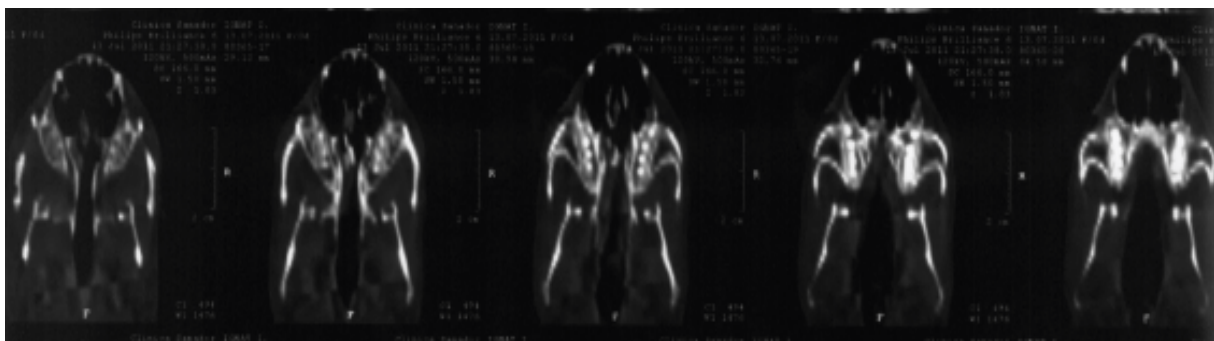


Fig. 9. CT images recorded on day 14 after disjunction: suggestive appearance of medio-sagittal suture separation.

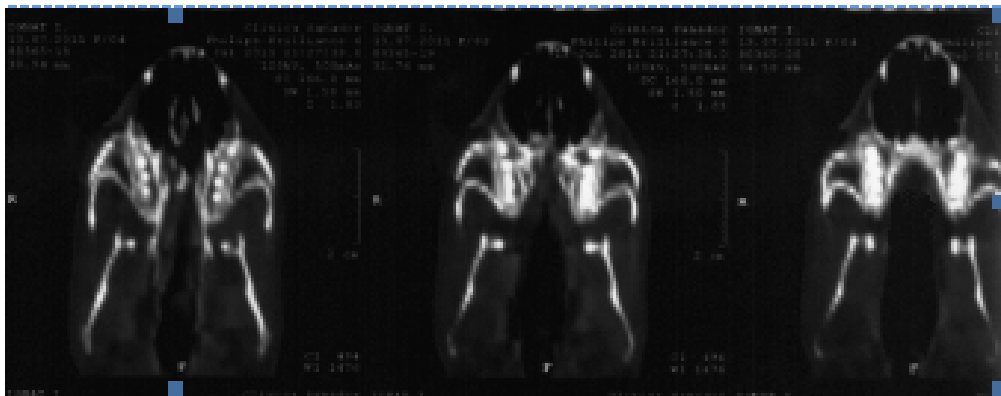


Fig. 10. CT images recorded at an interval of three weeks after contentment.

At 14 days after rapid disjunction, on axial angulation radiography (Fig. 8), a dehiscence area is recorded, corresponding to the separation of the maxillary bones.

CT evaluation of the effects on the bone structure caused by rapid disjunction was carried out in two points, namely, at the end of the active phase of expansion (Figs. 9, 10) and a three-week interval after contentment.

Therefore, Figure 9 shows medio-sagittal suture separation, which is more obvious in the anterior

segment of the palate. The images obtained from CT (Fig. 10), after three weeks of contentment, new bone formation was observed with obvious tendency to maintain the result obtained after rapid disjunction.

CONCLUSIONS

1. The newly formed bone represents a favorable substrate for tooth movement, allowing

apposition and resorption process development, the cornerstone of any fixed orthodontic treatment techniques.

2. According to the succession stages studied in the present experiment on laboratory animals, it was found that the ossification process has a net coverage tendency on the median palatine dehiscence suture area; nevertheless, it is placed under the reserve that our findings are not directly transferable to human tissue.
3. Enabling the fast and ultra-fast expansion technique remains accessible, and most often, after increasing diameters, treatment is continued with suitable fixed devices.
4. Therefore, structural bone changes obtained after disjunction and contention, mainly demonstrates that the therapeutic method induces permanent changes, offering an additional guarantee as in terms of maintaining the stability of the orthodontic treatment outcome.
5. On the control radiographs taken, it was observed the split of the medio-sagittal suture, and the optimal exposure, which highlighted the changes induced by disjunction, was the axial angulation.
6. On CT image it was observed medio-sagittal suture split, recorded on all subjects after disjunction, specifying that in the case of the quantitative determination, applied to the rear portion of the suture, this was recorded at a level of 30%, compared to the control (CT scanning technique offering a higher resolution for transverse dimensions measurements).

REFERENCES

1. Ali AM, Sharawy MM, An immunohistochemical study of collagen types III, VI and IX in rabbit craniomandibular joint tissues following surgical induction of anterior disk displacement. *J Oral Pathol Med* 25:78-85, 1996.
2. Al-Qawasmi RA, Hartsfield Jr JK, Everett ET, Flury L, Liu L, Foroud TM, *et al.*, Genetic predisposition to external apical root resorption. *Am J Orthod Dentofacial Orthop* 123:242-52, 2003.
3. Boboc G., *Tratamentul anomaliilor dento-maxilare. Principii si metode*, Edit. Medicală, Bucuresti, 1982.
4. Djasim UM, Hekking-Weijma JM, Wolvius EB, van Neck JW, van der Wal KG., Rabbits as a model for research into craniofacial distraction osteogenesis. *British Journal Oral and Maxillofacial Surgery* 46:620-4, 2008.
5. Dolce C. Kinniburgh AJ, Dziak R. Immediate early-gene induction in rat osteoblastic cells after mechanical deformation. *Arch Oral Biol* 41:1101-8, 1996.
6. Dorobăț V., Stanciu D., *Ortodonție și ortopedie dento-facială*, Edit. Medicală, București, 2009.
7. Garrett BJ, Caruso JM, Rungcharassaeng K, Farrage JR, Kim JS, Taylor GD., Skeletal effects to the maxilla after rapid maxillary expansion assessed with cone-beam computed tomography. *Am J Orthod Dentofacial Orthop*, 134:8-9, 2008.
8. Glassman AS, Nahigian SJ, Medway JM, Aronowitz HI., Conservative surgical orthodontic adult rapid palatal expansion: sixteen cases. *Am J Orthod*, 86:207-213, 1984.
9. Hunter CJ, Imler SM, Malaviya P, Nerem RM, Levenston ME, Mechanical compression alters gene expression and extracellular matrix synthesis by chondrocytes cultured in collagen I gels. *Biomaterials*, 23:1249-59, 2002.
10. Iwasaki LR, Haack JE, Nickel JC, Reinhardt RA, Petro TM., Human interleukin-1 beta and interleukin-1 receptor antagonist secretion and velocity of tooth movement. *Arch Oral Biol*, 46:185-9, 2001.
11. Liebschner MA., Biomechanical considerations of animal models used in tissue engineering of bone. *Biomaterials*, 25:1697-714, 2004.
12. Wang X, Mao JJ. Accelerated chondrogenesis of the rabbit cranial base growth plate upon oscillatory mechanical stimuli. *J Bone Miner Res*, 17:1843-50, 2002.