

THE IMPORTANCE OF CORNEAL TOPOGRAPHY AND TOMOGRAPHY IN THE DIAGNOSIS AND MONITORING OF KERATOCONUS

Cristina NICULA

Assoc. Prof. Dr., University of Medicine and Pharmacy "Iuliu Hațieganu", Department of Ophthalmology, Cluj-Napoca, Romania,
0722849575, niculacristina65@yahoo.com

Accepted December 27, 2022

Corneal imaging is of major importance in the diagnosis and the management of keratoconus. While corneal topography characterizes the shape of the anterior surface of the cornea, the tomography provides us a detailed analysis of the shape of anterior and posterior corneal surfaces, as well as the thickness/tissue distribution of the cornea. Most corneal topographical systems use the Placido disc principle which consists in the reflection of the concentric rings on the corneal surface. Unfortunately, it cannot give information's about the posterior surface of the cornea. The tomographers by using the Scheimpflug imaging, generates a three-dimensional description of the anterior and posterior corneal surface and gives information about corneal thickness. The indications for corneal topography and tomography include the diagnosis of corneal ectasia, management and observation of astigmatism and assessment for refractive surgery.

Key words: corneal topography, tomography, keratoconus.

INTRODUCTION

The term of topography is derived from Greek words "topos" (to place) and "grapho (to write). It represents a non-contact imaging technique that maps the shape and features of the corneal surface.¹

Corneal tomography is a detailed analysis of the shape of anterior and posterior corneal surfaces, as well as the thickness/tissue distribution of the cornea.¹

Cornea is an avascular, transparent tissue and accounts for 70% of the total refractive power of the eye(45D).¹ It has an elliptical anterior surface,

a horizontal diameter of 11.7 mm, a vertical diameter of 10.6 mm and a posterior circular surface with an average diameter of 11.5 mm.² It is known that cornea is aspherical with a prolate elliptical shape. The thickness of the cornea is variable: 0.52 mm at center, 0.67 mm at periphery and 1mm at limbus. The anterior radius curve is 7.8 mm, and the posterior radius curve is 6.5 mm. The corneal refractive index is 1,38. The structure of the cornea include 5 layers: epithelium, Bowman membrane, stroma, Descemet membrane and the endothelium. (Fig. 1)

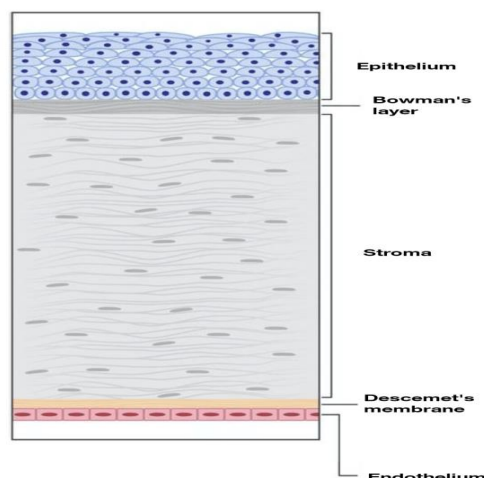


Figure 1. The structure of the cornea.

Cornea is divided into four zones:

- **The central zone** (apical zone): 3–4 mm: it is responsible for the high-definition vision.
- **The para central zone** (mid): 4–8 mm which is flatter than the central zone.
- **The peripheral zone**: 8–11 mm. It is the zone where the normal cornea flattens the most and becomes aspheric.
- **The limbal zone**. (Fig. 2)³

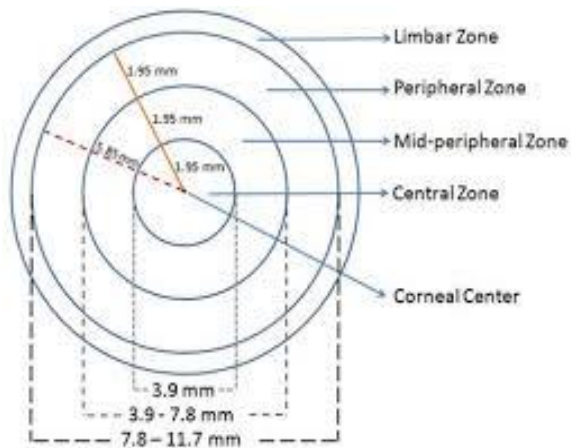


Figure 2. The zones of the cornea.

TOPOGRAPHY TECHNIQUES

The anterior surface of the cornea acts like a convex mirror, reflecting parts of the incident light.³ Several instruments were developed to estimate the anterior surface of the cornea by measuring the reflected light. In this regard, the reflection-based techniques are: Keratometry, keratoscopy, Placido photokeratoscopy, videokeratoscopy. The projection-based techniques are topography and Interferometry.⁴

KERATOMETRY

Keratometry was developed by Helmholtz. The calculations are based on the geometry of a spherical reflecting surface. The anterior surface of the cornea acts as a convex mirror and size image varies with its curvature.²

It measures the curvature of the anterior surface of the cornea from 4 reflected points within central 3 mm of the central zone. The range of keratometry values are dioptric power of 36 D to 52 D and the radius of curvature are between 6.5 mm to 9.38 mm. The devices used for keratometry measurements are the Helmholtz keratometer (Fig. 3), the Javal keratometer (Fig. 4) and the autorefractometer (Fig. 5).



Figure 3. Helmholtz keratometer.

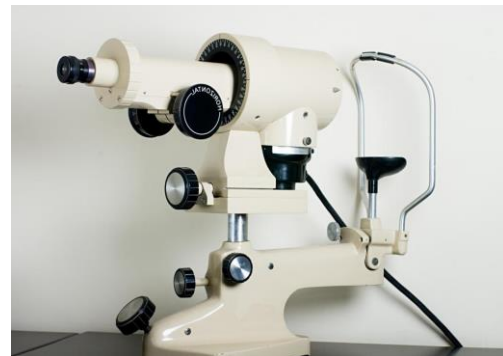

Figure 4. The Javal keratometer.



Figure 5. Autorefractometer.

Keratometry applications are represented by:

- is an objective method for determining the curvature of the cornea
- to estimate the amount and direction of astigmatism
- the ocular biometry for posterior chamber intraocular lens calculation
- to monitor pre and postsurgical astigmatism
- for the differential diagnosis of refractive anisometropia
- to diagnose and monitor keratoconus or another corneal ectasia
- for contact lens fitting by base curve selection

The limitations of keratometry are the following:

- it assumes the cornea to be spherical
- provides details on only 3 mm ignoring the peripheral cornea
- loses accuracy when measuring flat corneas
- small corneal irregularities preclude the use due to irregular astigmatism.

KERATOSCOPY

Keratometry is the outlier to actual corneal topography. The principle of this method is to use mires as concentric rings with several alternating bright and dark rings (Placido disk).⁵ The clinician evaluates the topographic abnormalities of the corneal surface by direct observation of images of mires reflected off the anterior corneal surface.²

Keratometry instruments that project multiple concentric rings (mires) on the cornea are the Placido disk keratometer (Fig. 5), the Photokeratometer and the Videokeratometer.

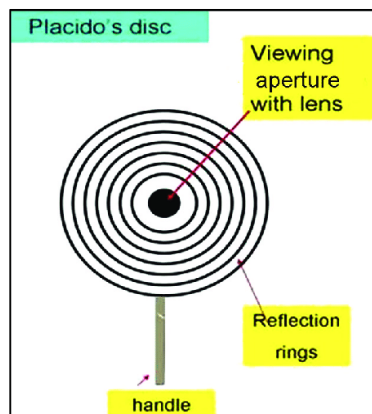


Figure 5. Placido disk keratometer.

The principle of Placido disk is that it uses the corneal reflections (Purkinje images) of bright rings.⁵ The Placido disk consists of equally spaced alternating concentric white and black rings and a central aperture for observing the corneal reflections of these rings over the cornea (Fig. 5). The observer views the concentric white rings (mires) reflected from the patient's cornea through a central +2D lens. Photokeratometry differs from Placido disk by the back illumination with a strobe flash and a camera replaces the observer's eye and makes pictures of the reflected mires. A photokeratometer is a qualitative reflection-based instrument. As clinical interpretation there are some patterns with which the clinician must be familiar: circular rings mean a spherical shape, the closer the mires the steeper the cornea, the wider

the rings the flatter the cornea, oval rings mean regular astigmatism. In cases of distorted images, we must deal with an irregular astigmatism (keratoconus) or corneal anomaly (Fig. 6).

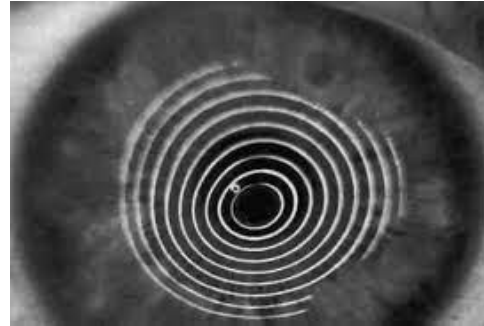


Figure 6. Distorted images in keratoconus.

There are some disadvantages of Placido disk such as:

- Small degree of abnormalities of corneal shape are not easily identified
- Limited data points
- It is severely affected by tear film disturbances
- It cannot be used in corneal edema/ corneal ulcers/epithelial defects
- Clinically significant cylinder (up to 3 D) may not be diagnosed
- Subtle irregularities cannot be detected
- The patient is exposed to high light
- Anatomy of the nose and orbit may limit field size and restrict the corneal area that can be examined.²

Because of these reasons nowadays the use of Photokeratometer was abandoned.

The principles of Placido ring-based videokeratometers were described in 1880 by Antonio Placido.⁶ These devices use concentric rings of light in association with a digital camera to capture images of the reflection of rings by the anterior surface of the cornea and are processed by some algorithms. More sophisticated Placido-disk-based devices associate the Placido-disk with other technologies such as Scheimpflug images or scanning-slit technology.¹

COMPUTER TOPOGRAPHY SYSTEMS

Nowadays, tomography is most commonly used for the diagnosis of corneal ectasia. Corneal topographic system (CTS) implies computerized, video assisted techniques which provides a detailed information about the shape of the corneal surface, allowing both qualitative and quantitative measurements of the cornea.

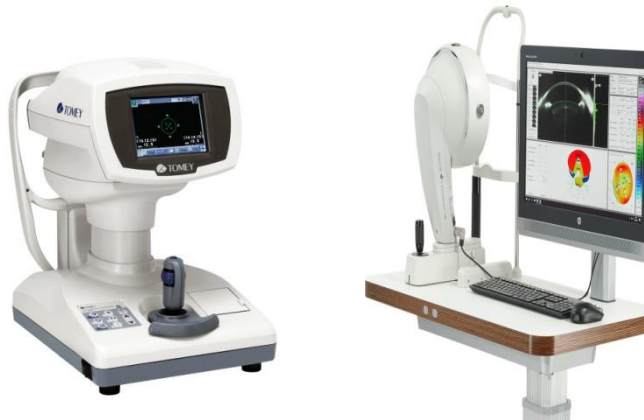

Figure 7. Corneal topographers (Pentacam).

Most corneal topographers evaluate 6000–10000 specific points across the corneal surface and offers an excellent accuracy (Fig. 7).

The basic unit of CTS consists of projection device, video camera, digital computer attached to a slit lamp chin rest.

Classically, the corneal topography is defined as a non-invasive examination which explores both qualitatively and quantitatively the morphology of the cornea.⁷

The indications of corneal topo/tomography are the following:

- Diagnosis, screening, and management of keratoconus
- Detection of other corneal ectasias
- Perfection of contact lens fitting, incision placement and intrastromal ring placement in keratoconus
- Cataract and refractive surgery assessment
- Post surgery astigmatism: Post cataract surgery and post keratoplasty corneal astigmatism can be studied with the topographer and selective suture removal or other interventions can be planned
- Surgical planning in cases with corneal astigmatism: limbal relaxing incisions and other methods of topography guided incision placement are used by surgeons to reduce post operative astigmatism.⁸

The modern corneal topo/tomography systems are represented by Placido disc based –Eyes Sys, slit-scan based-Orbscan, Scheimpflug image based-Pentacam and OCT based-IOL Master 700.

This presentation will describe the Pentacam topographer (Oculus, Wetzlar, Germany). The principle of Pentacam topographer is that a single rotating Scheimpflug camera along with a 14 mm monochromatic slit illumination system, composed of blue light emitting diodes (475 nm) rotate along

the optical axis of the eye, perpendicular to each other and gives slit images of the cornea from 0° to 180° (Fig. 8).

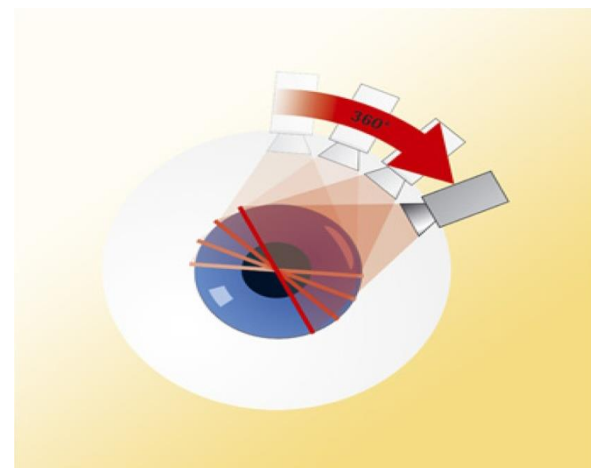


Figure 8. Scheimpflug camera principle.

The slit beam produces an illuminated section which is imaged 12–50 times by the rotating Scheimpflug camera, corresponding to specific angles along the optical axis.

The data obtained from these images is used to assess the anterior and posterior surfaces of the cornea as well as the corneal thickness/tissue distribution.⁹

The advantages of Pentacam are the following:

- Takes 50 meridional sections through center of the cornea which allows the system to realign the central thinnest point of each section before it reconstructs the corneal image, and it eliminates any eye movement occurring during the examination
- Enables of cornea with severe irregularities (keratoconus)
- Enables calculation of pachymetry from limbus to limbus.

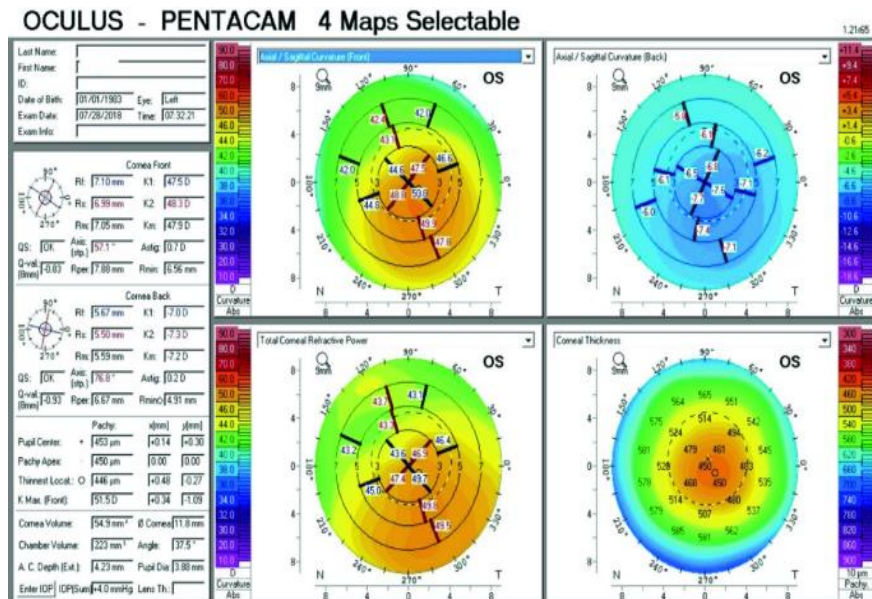


Figure 9. Color coded topographic maps.

COLOR CODED TOPOGRAPHIC MAPS

The Pentacam gives color coded topographic maps which are the most useful and most used display formation. The color coding shows cool colors (black, blue, azure) which means flatter surfaces, warm colors (orange, red, white) which means steeper surfaces and normal (yellow, green) for normal surfaces² (Fig. 9).

SCALES

There are two types of scales, the absolute scale and the normalized one.

The absolute scale is used in routine practice for screening. When using an absolute scale, colors are permanently assigned to K values. The maximum is 50 D, and the minimum is 35D. Each color has 1.5 D interval. Under 35 or beyond 50 D for each color is 5D interval. Yellow indicates mild steepening and orange corresponds to moderate steepening.² The main disadvantage is that it does not show subtle changes of corneal curvature.

In the **normalized scale** the cornea is divided into 11 equal colors. Colors representing K values can vary from map to map. There is a smaller difference between maximum and minimum values in the normalized scale: maximum 49.5 D and minimum 40.5 D. Green often represents normal curvature. The advantage is that it shows a detailed aspect of the abnormalities of the corneal surface, but the disadvantage is that the colors of two different maps cannot be compared.²

The Pentacam include the quantitative indices integrated such as: ISV=index of surface variance, IVA= index of vertical asymmetry, IHA= index of height asymmetry, IHD= index of height decentration ABR= aberration coefficient, KI=keratoconus index, CKI=center keratoconus index, R min = radius minimum, KISA index, I-S=inferior-superior.

To interpret the Pentacam routinely we use the following **maps**:

- Sagittal curvature maps
- Anterior elevation maps (front)
- Posterior elevation maps (back)
- Tangential maps
- Pachymetry or corneal thickness
- Belin-Ambrosio Enhanced Ectasia Display
- Quantitative indices

The anterior sagittal curvature maps reveal the anterior surface dioptric power. It fixes the curvature centers on the optical axis and considers the corneal surface to have a spherical geometry.¹⁰ Steep areas appear in hot colors (red/orange) and flat areas in cold colors (green/blue) (Fig. 10). The parameters has to be read in a 5 mm circle.

The normal pattern is the **symmetric bowtie**. The normal I-S (inferior-superior) difference is $<1.5\mu$ (inferior higher value than superior) (Fig. 11).

In regular astigmatism, the vertical meridian of the cornea is slightly steeper than the horizontal. In with the rule astigmatism, there is a symmetric bow-tie and equal in size (SB).

When the horizontal meridian of the cornea is steeper it is against the rule astigmatism and the symmetric bow-tie is horizontal. In oblique astigmatism, the symmetric bow-tie is oblique.

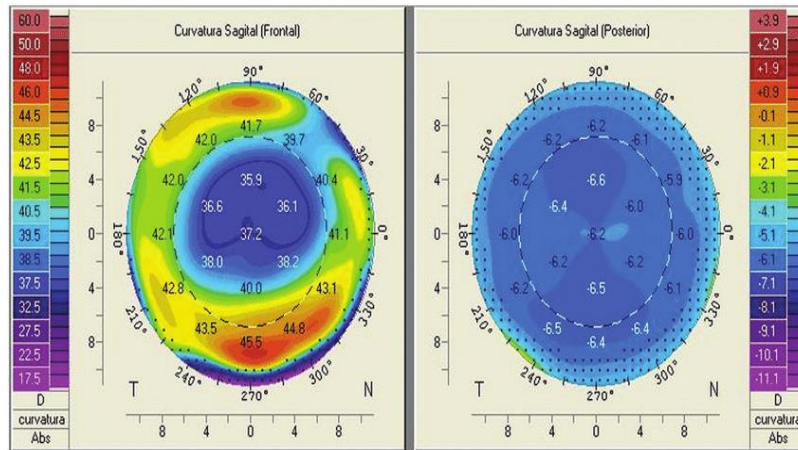


Figure 10. Anterior Sagittal maps.

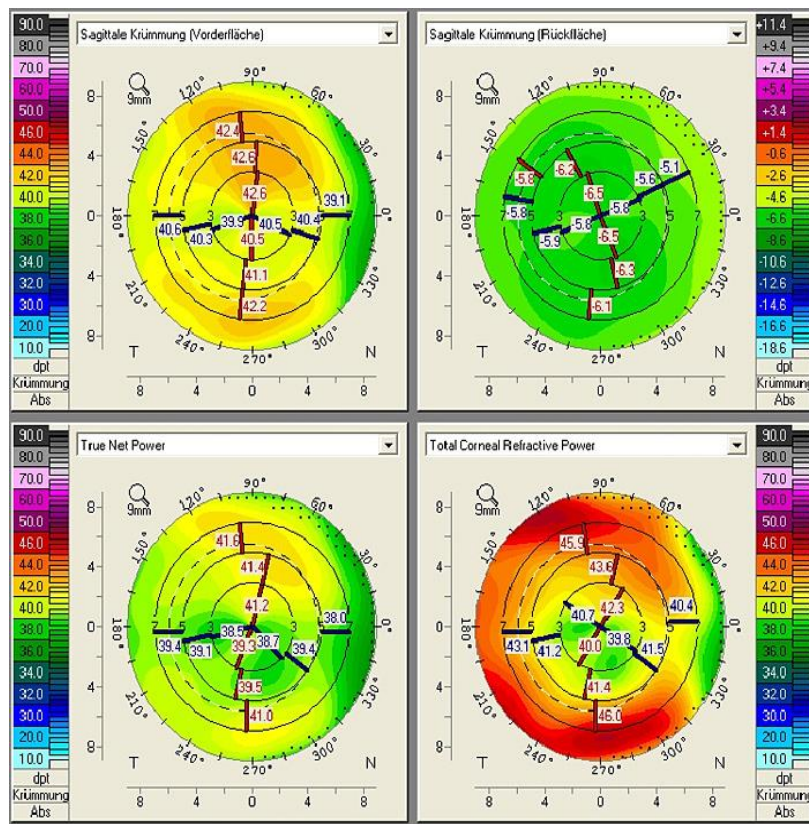


Figure 11. Symmetric bowtie.

The abnormal patterns:

- **Round**: the steepest part of the cornea takes a round hotspot shape;
- **Oval**: the steepest part of the cornea takes a oval hotspot shape;
- **Superior steep (SS)**: the steepest part of the cornea (hotspot) is localized in the upper part of the cornea;
- **Inferior steep (IS)**: the steepest part of the cornea is localized in the inferior part of the cornea;
- **Symmetric bowtie (SB)**: lobes of the bowtie are equal in size and have the same axis (symmetric type of keratoconus);
- **SB/SRAX** with angulations ($>22^\circ$) between the axes of the lobes (“lazy 8” pattern);
- **Asymmetric bowtie/inferior steep (AB/IS)**: asymmetric bowtie with the inferior lobe bigger than the superior one; if $I-S > 1.5 D$ is keratoconus;
- **Asymmetric bowtie/superior steep (AB/SS)**: asymmetric bow-tie superiorly steep;

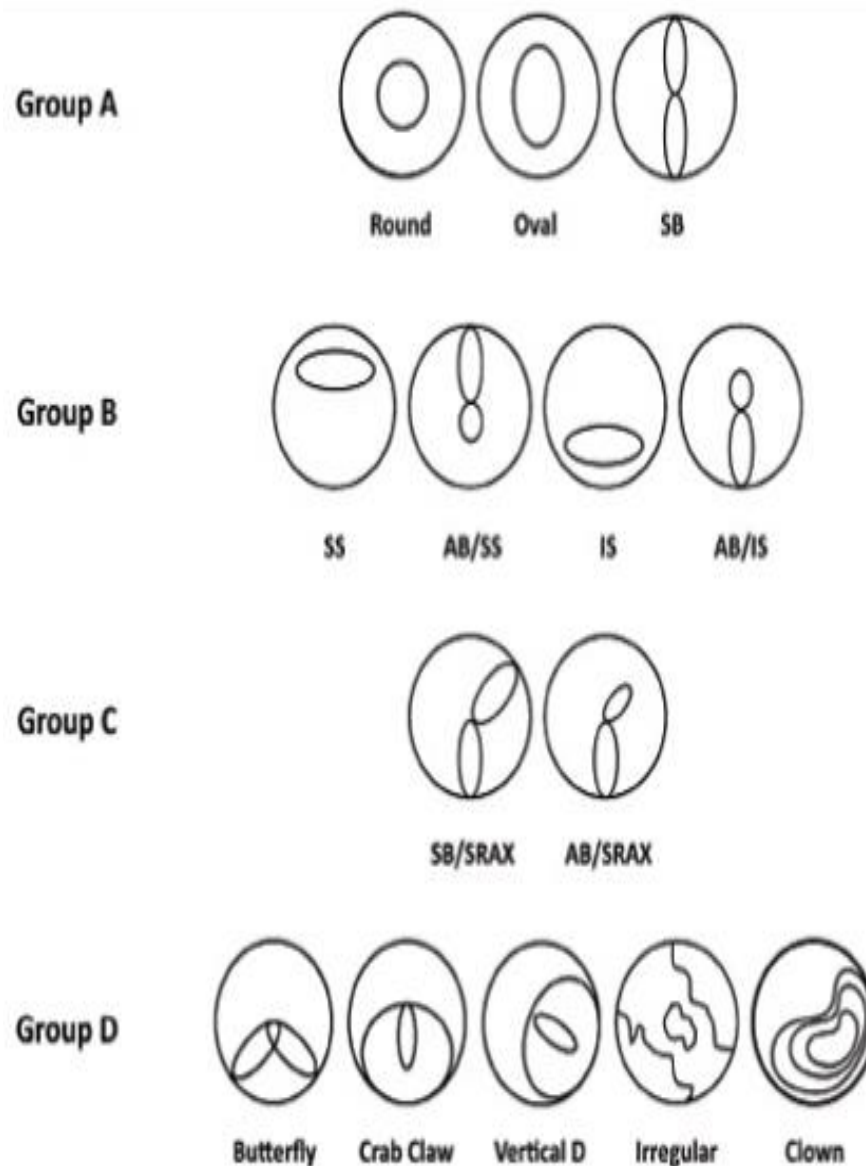


Figure 12. Abnormal patterns of corneal topography.

- It is risky if the difference between two symmetric points on the 5 mm central circle is $>2.5D$ (Fig. 12).

ELEVATION MAPS

The principle of elevation maps is that the patient's cornea is compared to normative age related data base and the elevation/depressions are calculated both in anterior (A) and posterior(B) surface. Ideal, the reference surface (RS) has 8 mm. All elevation points located above RS are considered +. The depressions points located below the RS are considered -. **Best fit sphere (BFS)** quantifies the shape measured. Best fit toric

ellipsoid (BFTE) quantifies parameters of that surface (Fig. 13).

The BFT **normal model** is represented by the hour glass(with the rule, regular astigmatism), elevation value of the anterior surface $<+12\mu$ and elevation value of the posterior surface $<+15\mu$.

The abnormal patterns are:

- **Skewed hour glass**, when misalignment appears during capture, or the cornea is distorted
- **Isolated island** in distorted cornea
- **Cone location:** central (3 mm)/paracentral (3–5 mm)/peripheral (>5 mm) (Fig. 14)¹⁰.
- if cone is peripheral, the aspect is the **kissing birds** sign (Fig. 15).

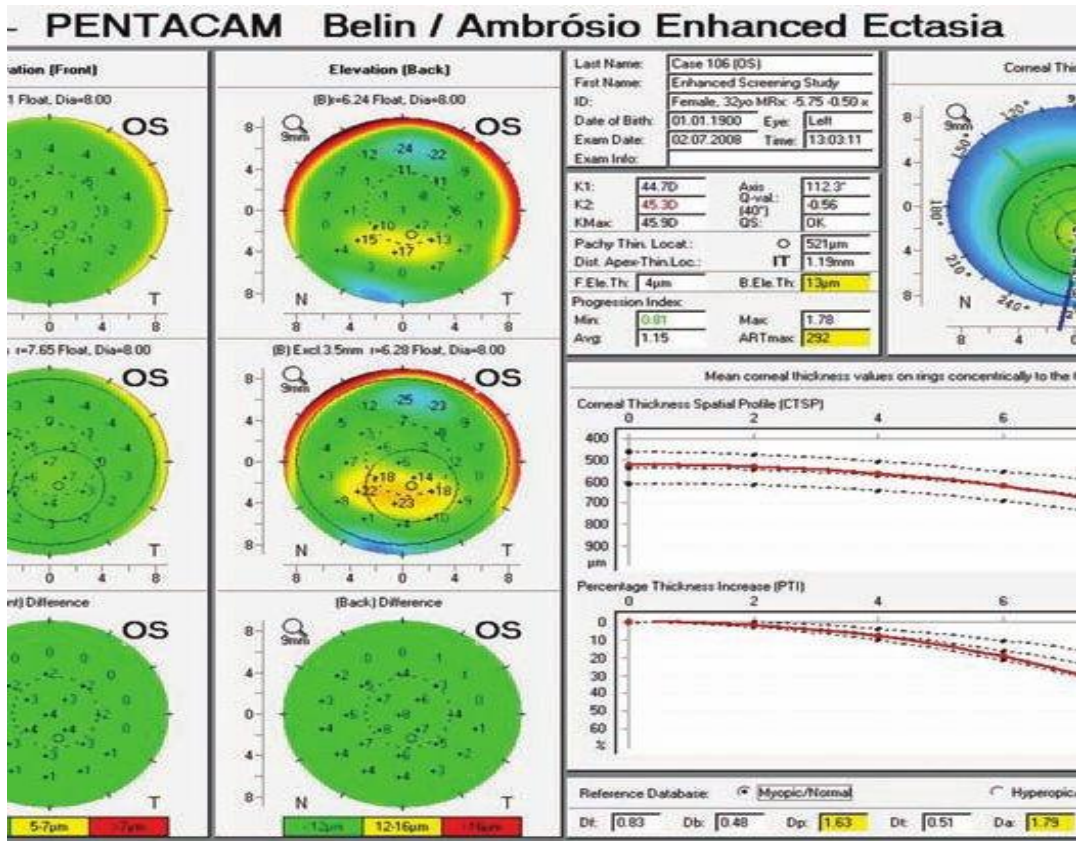


Figure 13. Elevation maps.

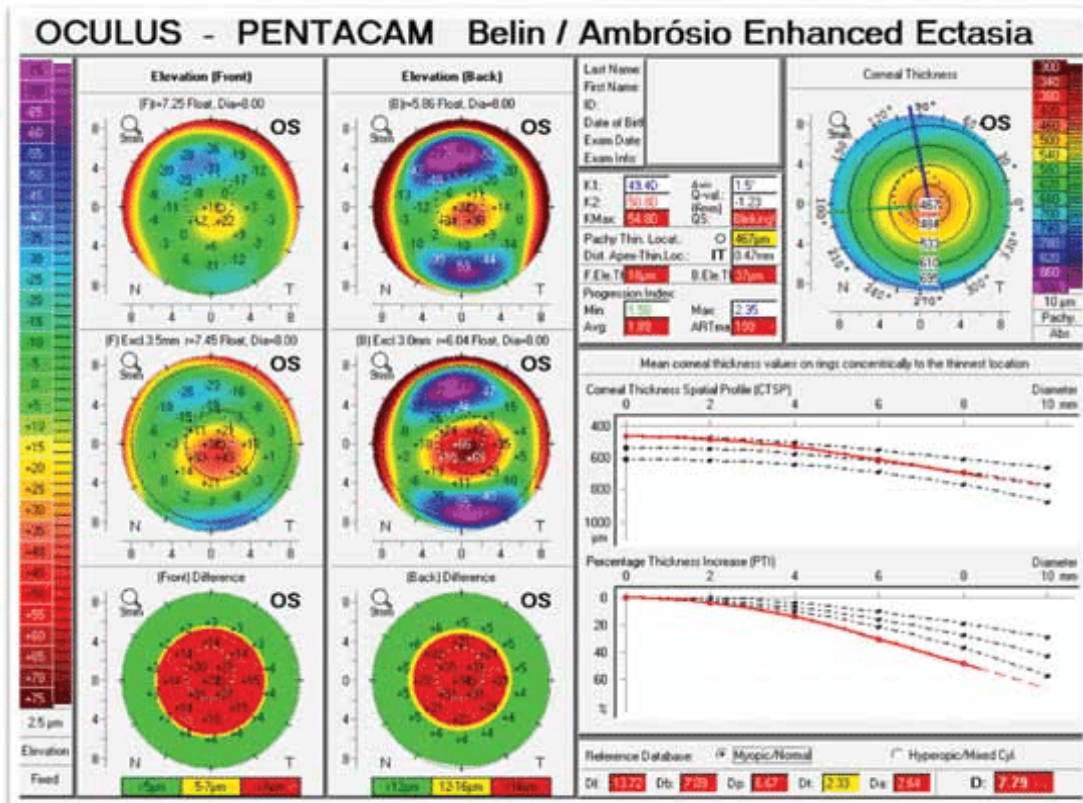


Figure 14. Keratoconus.

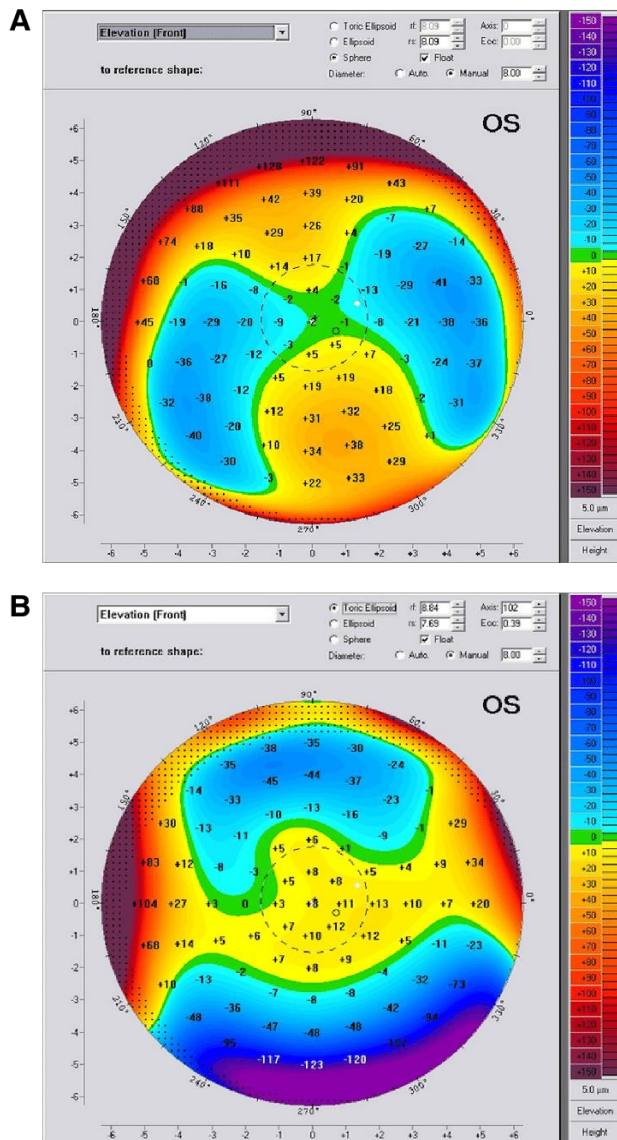


Figure 16. The kissing birds sign.

The tangential maps provide a better geographical representation of the cornea. Is the best indicator of the conical shape than power.⁴

PACHYMETRY MAPS

The computer measures the thickness of the cornea at all points depending on the elevation maps. The difference between the front and back surface elevations indicates the corneal thickness. It gives information about the corneal apex and the thinnest location (TL). The difference between superior and inferior points has to be less than 30 μm. The normal map is concentric (Fig. 16).

The abnormal patterns are:

- the horizontal displacement of TL
- **Dome shape:** vertical displacement of TL

- **Bell shape:** thin band of cornea inferiorly-PMD
- **Keratoglobus** – generalized thinning (Fig. 17)

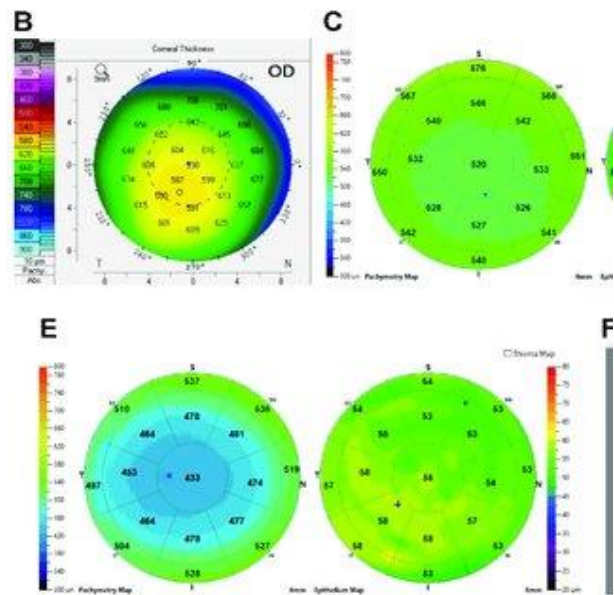


Figure 17. Pachymetry maps.

INTEGRATED INDICES

- The integrated indices helps to differentiate normal corneas from keratoconus, by quantifying the irregularity of the corneal morphology.¹⁰
- **1. ISV**
- Is the index of surface variance. It measures as standard deviation of individual sagittal radii from mean curvature. A value > 37 is yellow and is considered abnormal. A value >41 is red and is considered pathological.⁴
- **2. IVA**
- Is the index of vertical asymmetry and represents the mean difference between superior and inferior curvature. A value > 0.28 is abnormal and a value > 0.32 is considered pathological.⁴
- **3. IHA**
- Represents the index of height asymmetry. Is the mean difference between corneal elevation in superior hemisphere and inferior hemisphere in the horizontal meridian. A value >19μm is abnormal and a value >21μm is considered pathological.⁴

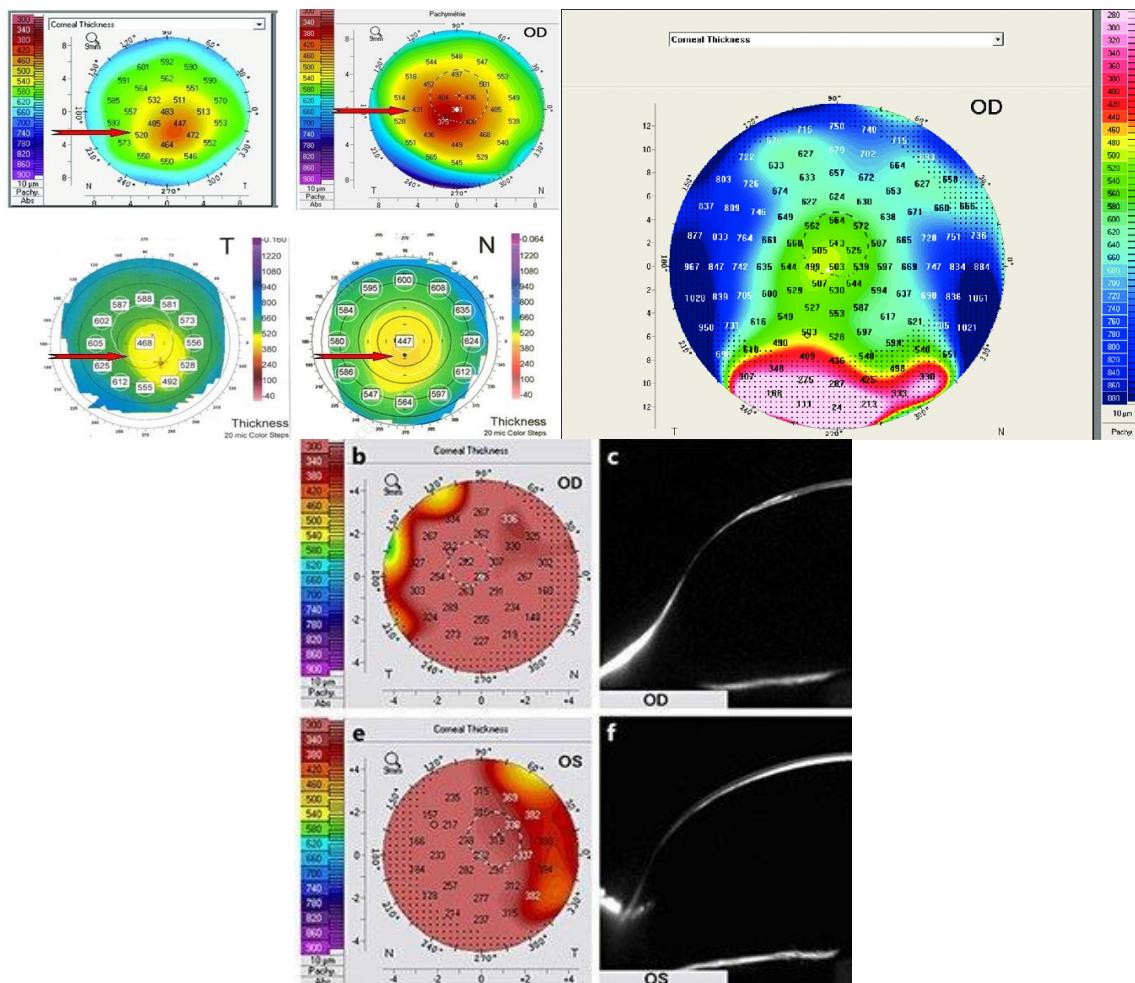


Figure 17. Abnormal patterns in pachymetry maps.

4. IHD

Is the index of height decentration. It measures vertical the degree of vertical decentration of corneal elevation data on a ring with radius of 3 mm. A value of >0.014 is abnormal and a value >0.016 is considered pathological.⁴

5. KI

Is the keratoconus index. It represents the ratio between mean radius values in upper half and lower half of the cornea. A value >1.07 is abnormal and a value > 1.07 is pathological.⁴

6. CKI

Is the central keratoconus index. It represents the ratio between mean radius of curvature in a peripheral Placido ring and mean radius of curvature in the central ring. A value >1.03 is abnormal.⁴

7. R min

Is the radius minimum and denotes maximum steepness of the cone. It represents the smallest

radius of sagittal / axial corneal curvature. A value <6.71 is abnormal (Fig. 18).

8. I-S index

This index is based on Placido topography data. It consists of averaging keratometric values obtained at different points on the superior and inferior cornea.⁴ A cut-off value of $>1.4D$ indicates subclinical keratoconus and a value $> 1.9D$ is associated with clinical keratoconus.⁴

9. KISA%

The KISA% index was derived from central K, I-S, the astigmatism index (AST), which quantifies the degree of the regular corneal astigmatism and SRAX index, an expression of irregular astigmatism occurring. A value between 60 to 100 it indicates suspect of keratoconus, while a value higher than 100 is a diagnosis of keratoconus. KISA has a high sensitivity and specificity in the diagnosis of clinical keratoconus.¹¹⁻¹³

10. Belin-Ambrosio Enhanced Display BAD_D

The Pentacam topographer proposes a mode of representation of corneal elevation adapted to the detection of subclinical forms of keratoconus. The BAD_D display integrates anterior, posterior elevation and pachymetry data. It gives a complete overview of the corneal shape, calculating changes in corneal thickness overall 360° of the cornea.

It is a quick screening tool to diagnose keratoconus.^{4,14} The first part of BAD_D display is the

corneal thickness profile which represents the average progression from thinnest point to periphery. The normal value is 0.81.1 mm (Fig. 19).

- **Abnormal** patterns are:
- Quick slope when red lines leaves before 6 mm-avg>1.1mm and denote keratoconus.
- S-shape when red line has a “Sharpe S”-avg >1.1mm and is associated with keratoconus (Fig. 20).

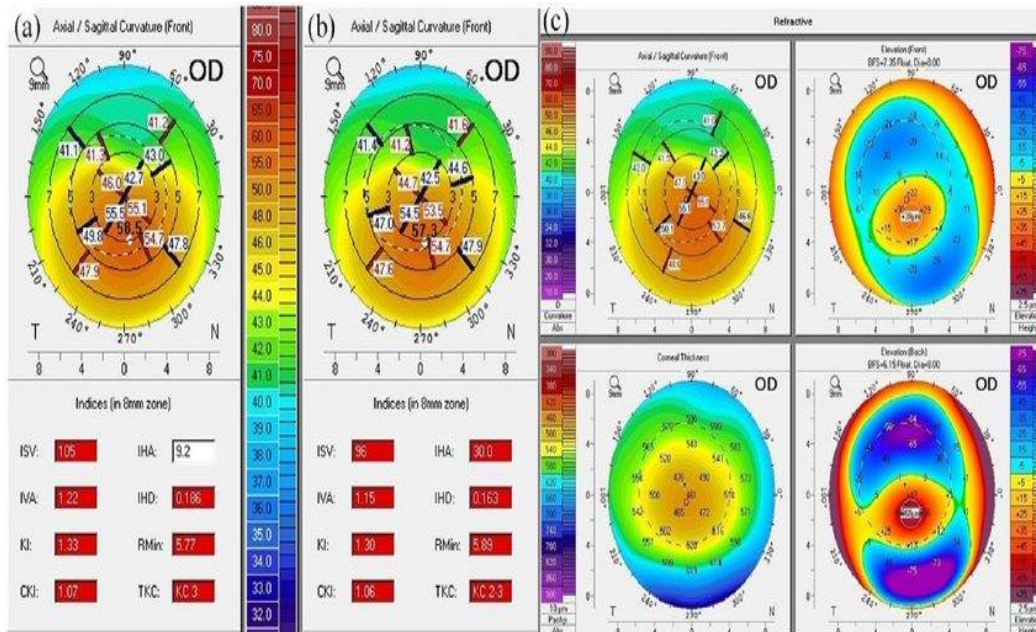


Figure 18. Integrated Indices.

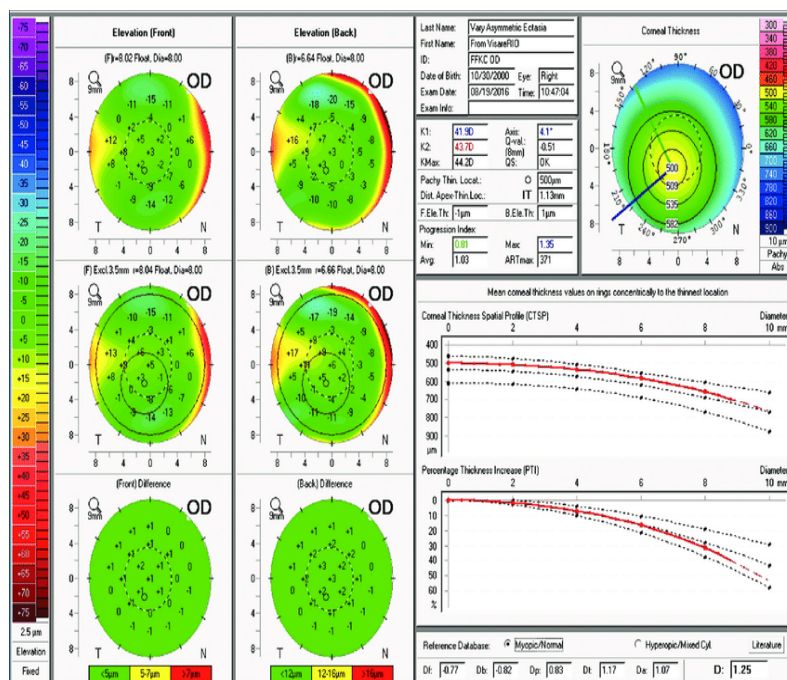


Figure 19. BAD_D display-normal aspect.

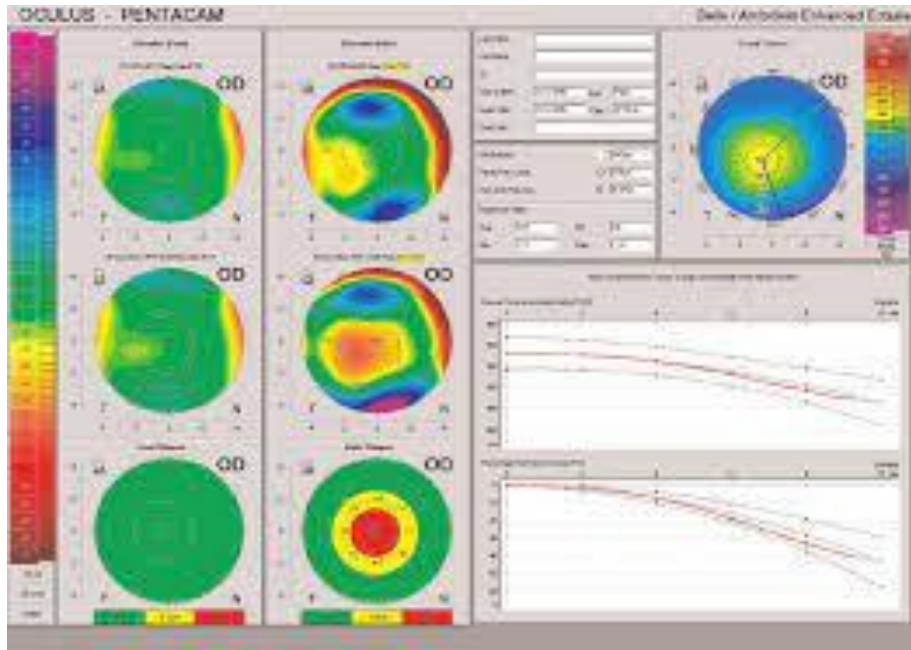


Figure 20. Abnormal patterns of BAD_D display.

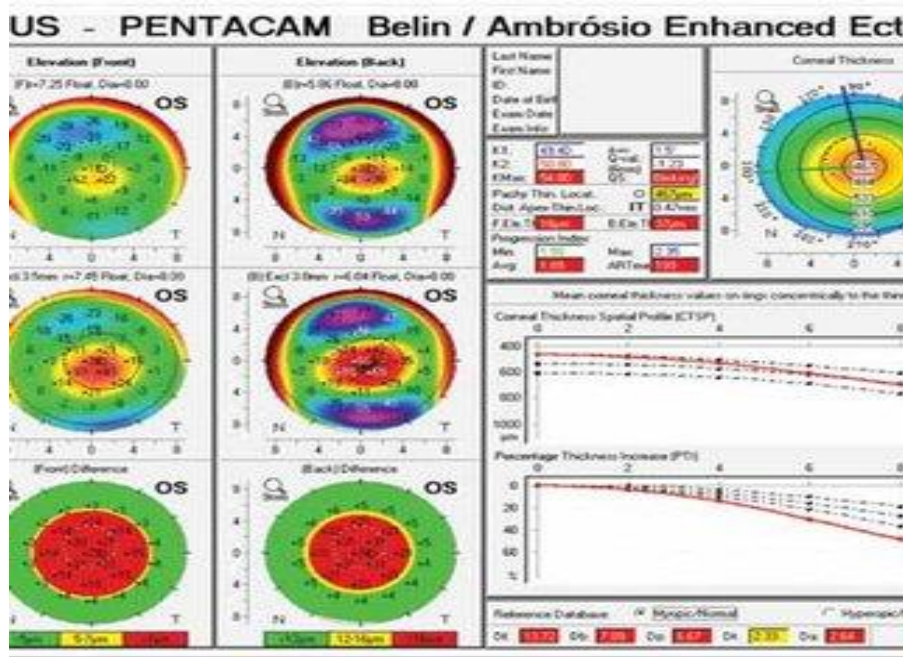


Figure 21. Ambrosio relational thickness.

- Another part of BAD_D is the pachymetry progression index (PPI) which is the progression value at each meridian from the thinnest point

11. ART Max

Is the Ambrosio relational thickness. It represents the ratio between the thinnest point and PPI. It distinguishes keratoconus from normal corneas. A value <412 μm denotes keratoconus (Fig. 21)¹⁵.

The Pentacam provides the modern classification of keratoconus- the ABCD classification, where A=anterior surface, B=posterior surface, C=corneal thickness and D=distance best corrected visual acuity (Fig. 22).

- Clinical applications of corneal topography
- Corneal topography is indicated for:
 - Preoperative and postoperative assessment of the refractive patient
 - Detecting irregular astigmatism

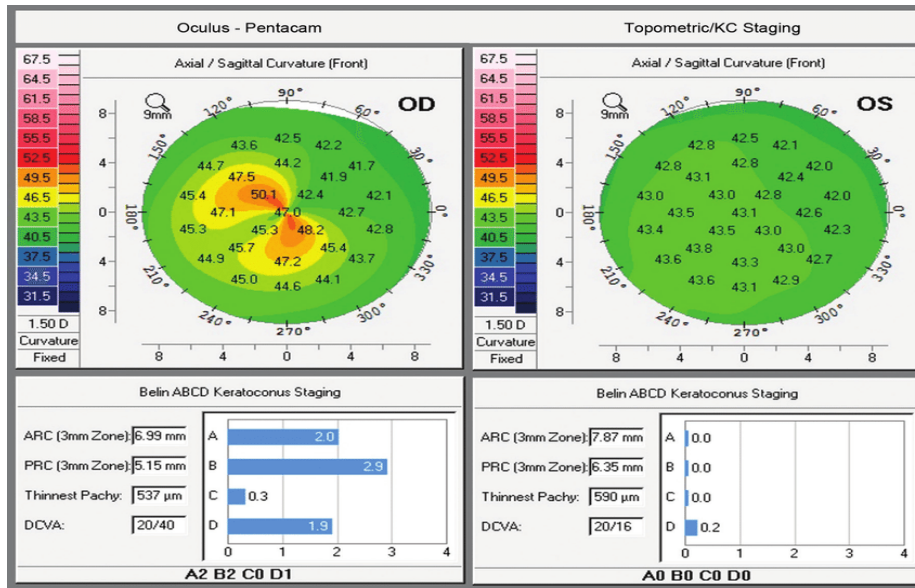


Figure 22. The ABCD classification of keratoconus.

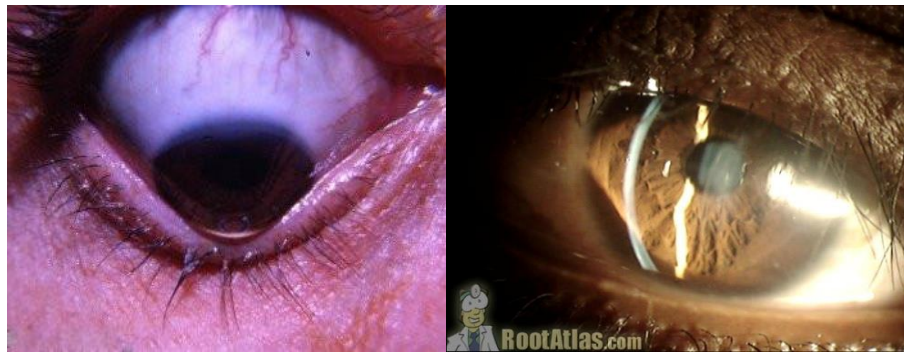


Figure 23. Classical signs of keratoconus.

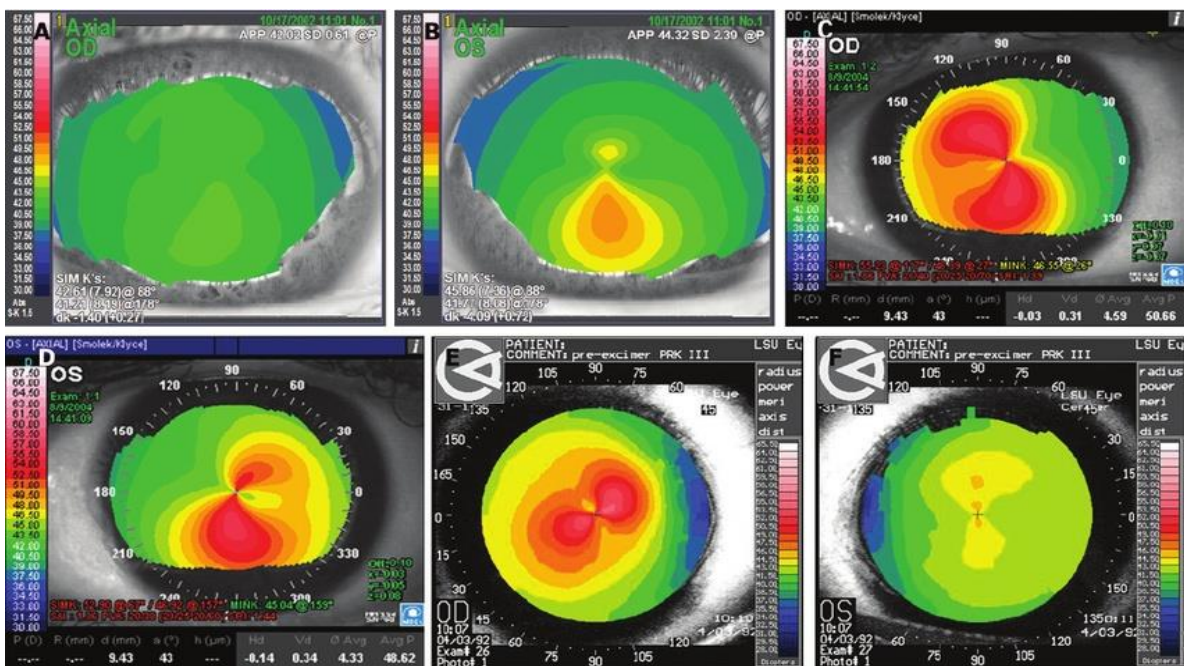


Figure 24. Keratoconus patterns in corneal topography.

- Corneal ectasias (keratoconus, marginal pellucid degeneration, keratoglobus, post Lasik ectasia)
- Follow-up of corneal ulcers /abscesses
- Post traumatic corneal scarring
- Contact lens fitting
- Artificial intraocular lens power calculation.
- Keratoconus

Is a bilateral non- inflammatory ectatic corneal dystrophy, characterised by irregular shape of the cornea secondary to stromal thinning and protrusion, irregular astigmatism and myopia and in late stages decreased visual acuity.¹⁶ The disease onset is at puberty and has a rapid evolution between 12 to 20 years of age.

The etiology of keratoconus is multifactorial and includes: heredity, family history, enzyme theory, atopy, eye rubbing, inflammation, oxidative stress, molecular corneal changes, sexual hormones, prolactin-induced protein.¹⁷

Clinical features present in keratoconus are: irregular astigmatism, blurred vision- even when wearing glasses and contact lenses, glare at night, phantomatic images, light sensitivity, frequent prescription of glasses, eye rubbing, diplopia or polyopia. The slit lamp exam reveal the classical signs of the disease:

- Munson sign (angulation of the lower eyelid during inferior gaze due to the corneal protrusion)
- Rizzutti sign: conical reflection on the nasal cornea when a penlight is shown from the temporal part (Fig. 23).

The diagnosis of keratoconus is established by the slit lamp exam, refraction, retinoscopy (scissor reflex), ophthalmoscope (oil droplet), keratoscope and Placido disk (distorted images).

- Corneal topography and tomography is the most important examination for keratoconus diagnosis. The common topographical pattern is “lazy 8” (Fig. 24).

REFERENCES

1. Fan R, Chan T, Prakash G, Jhansi. Applications of corneal topography and tomography: a review. *Clinical and Experim Ophthalmology*, 2017, 46, 2, 1-30.
2. Wachler BB. Modern management of keratoconus. Ed Jaypee Brothers Medical, New Delhi, 2008, 33-34.
3. Sinjab M. Corneal topography in clinical practice (Pentacam System). Basics and clinical Interpretation. Ed. Jaypee Brothers Medical Publisher, New-Delhi, 2012, 15-39, 39-51, 89-101.
4. Gatinel D, Malet J, Azar ST. Corneal elevation topography: Best Fit sphere, elevation distance, asphericity, toricity and clinical implications. *Cornea*, Lippincott Williams & Wilkins, 2010, 1-8.
5. Knoll HA. Corneal contours in the general population as revealed by keratoscope. *American Journal of Optometry and Archives of American Academy of Optometry* 1961; 38:389-397.
6. Brody J, Waller S, Wagoner M. Corneal topography – history, technique, and clinical uses. *Int Ophthalmol Clin*, 1994; 34: 197– 207.
7. Klyce SD. Computer-assisted corneal topography. High-resolution graphic presentation and analysis of keratoscopy. *Invest Ophthalmol Vis Sci*, 1984; 25(12):1426-1453.
8. Feldman B, Prakash G, Bunya V, Akkara JD, Bernfeld E, Chen M. Corneal topography. *American Academy of Ophthalmology*, 2022.
9. Gokul A, Vellara HR, Patel DV. Advanced anterior segment imaging in keratoconus: a review. *Clinical and Experimental Ophtalmol*, 2017, 46(2), 1-24.
10. Cava-Martinez F, Sanchez F, Fernandez-Pacheco DG. Corneal topography in keratoconus: state of the art. 2016. *Eye Vis(Lond)*, 3-5.
11. Montalbán R. Caracterización y validación diagnóstica de la correlación de la geometría de las dos superficies de la córnea humana. Alicante: Universidad de Alicante; 2013.
12. Albertazzi R. Queratocono: pautas para su diagnóstico y tratamiento. Buenos Aires: Ediciones Científicas Argentinas; 2010.
13. Rabinowitz YS, Rasheed K. KISA% index: a quantitative videokeratography algorithm embodying minimal topographic criteria for diagnosing keratoconus. *J Cataract Refract Surg*. 1999; 25(10):1327–35.
14. Rabinowitz Y. Keratoconus. *Surv Ophthalmol*. 1998; 42(4):297–319.
15. Ambrósio R Jr, Alonso RS, Luz A, Coca Velarde LG. Corneal-thickness spatial profile and corneal-volume distribution: tomographic indices to detect keratoconus. *J Cataract Refract Surg*. 2006; 11:1851-9.
16. Belin MW, Khachikian SS. Corneal diagnosis and evaluation with the OCULUS Pentacam. *Highlights of Ophthalmology*. 2007; 35:5-8.
17. Loukovitis E, Koseis N, Gatsioufas Z, Kozei A, Tsotridou, Stoila M, Koronis S, Sfakianis K, Tranos P, Balidis M, Zachatadis Z, Mikropoulos D, Anogeianakis G, Katsanos A, Konstas A. The Proteins of Keratoconus: a Literature Review Exploring Their Contribution to the Pathophysiology of the Disease. *Advances in Therapy*, 2019, 36, 2205-2222.